


The Diamond ring



Presenter:

Dr Bassim Albizreh, MD, echo subspeciality fellow,
Heart hospital, Doha, Qatar

- 
- 39 y old man
 - No known chronic illness
 - married, non smoker, occasional alcoholic. no drug abuse
 - Came to ER with sever headache, fever 39, confused, no respiratory symptoms.
 - was not cooperative and not giving history

On exam

- 115/78 . P90 t 39
- chest : clear equal bilateral.no tachypnea
heart :s1, s2 no additional sound
abdomen : soft lax, no tenderness.

CT head done

- normal

- PATIENT HEMODYNAMICALLY NOT STABLE ,
HYPOTENSION 68/44 , PULSE 140 , RR 22 ,

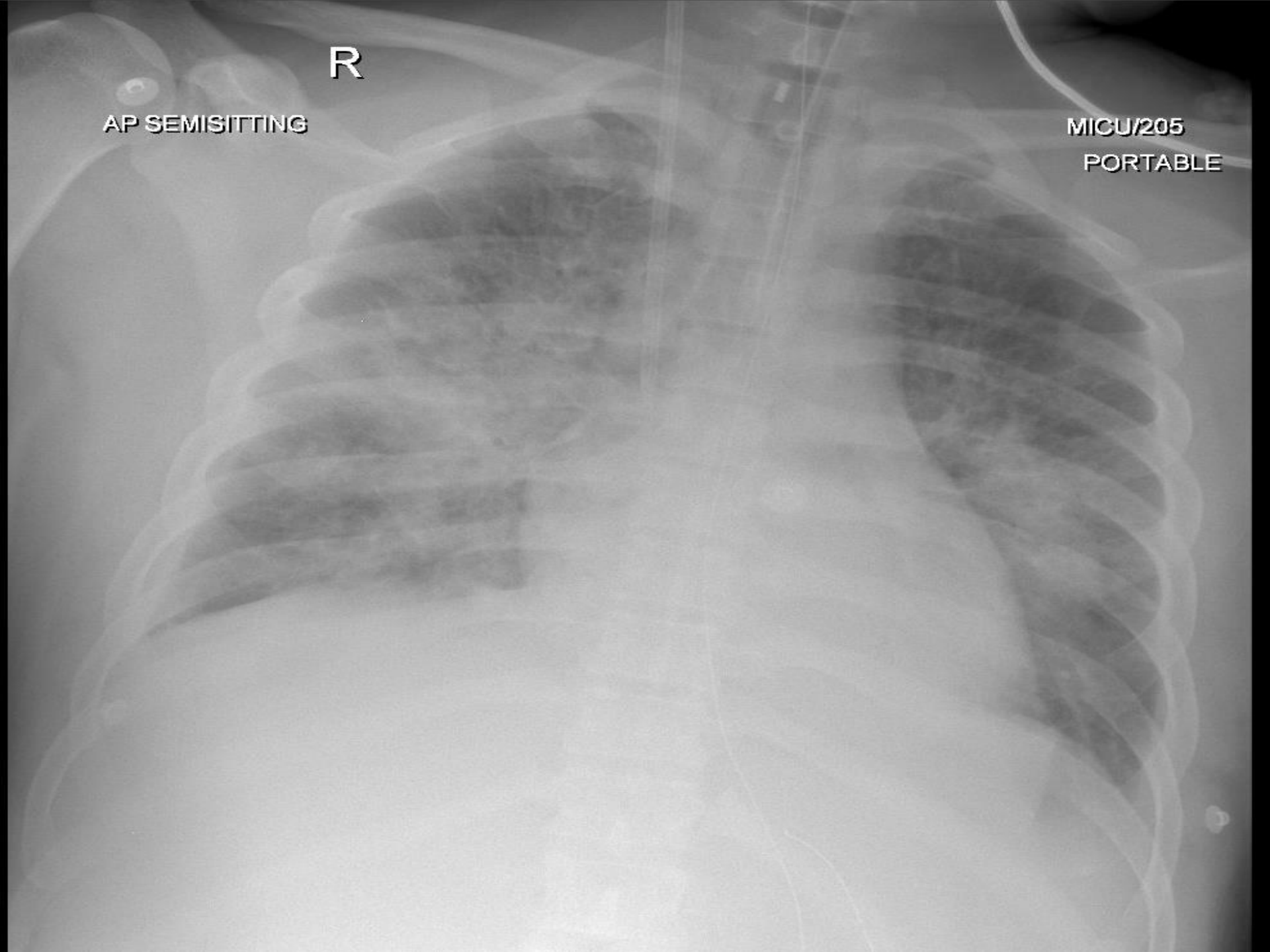
CANCEL LP , contact ICU

ICU : pt became agitated when reached MICU
, desaturated and was intubated and sedated

R

AP SEMISITTING

MICU/205
PORTABLE

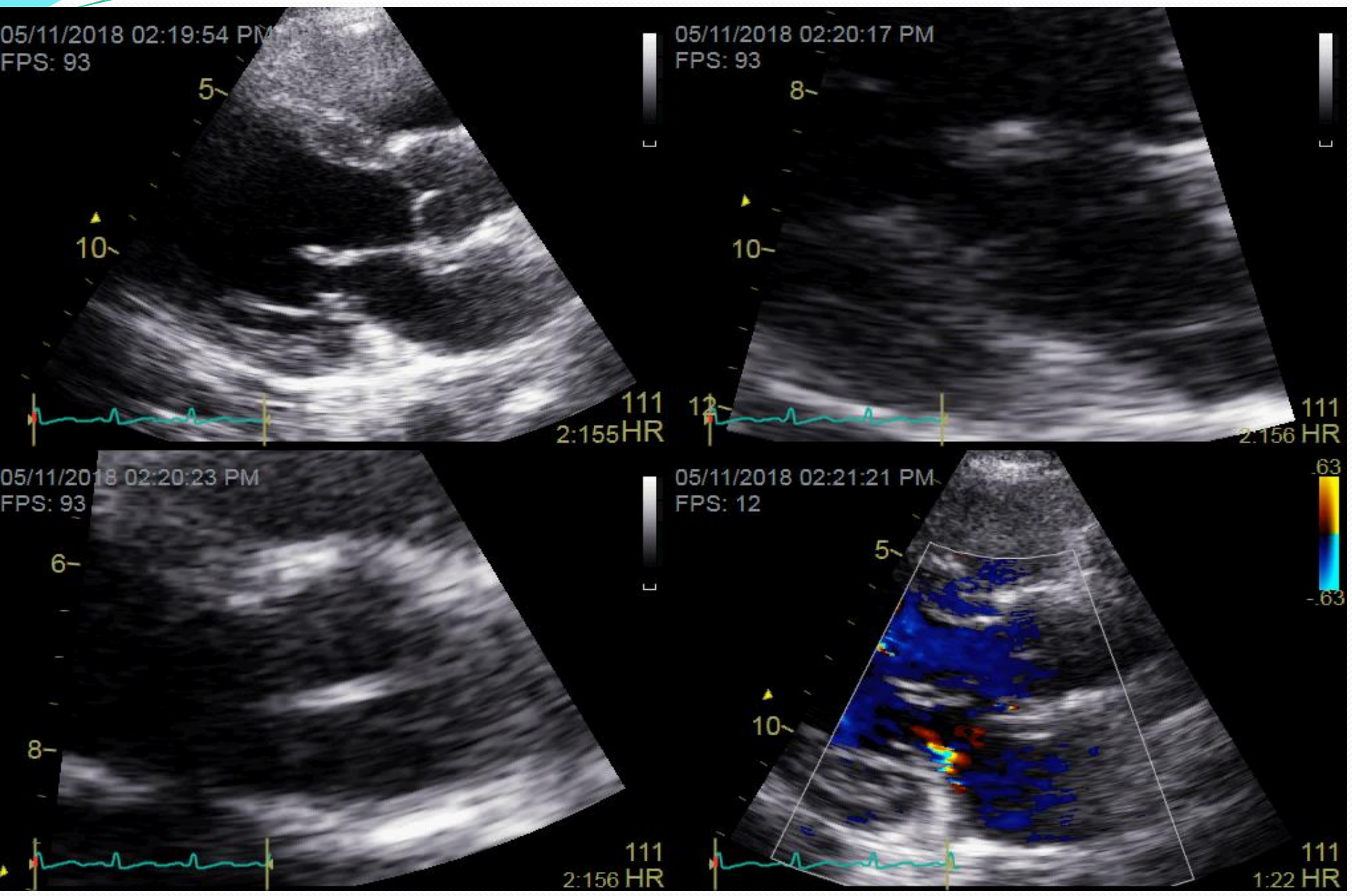


General Hematology	
WBC	H 13.6
RBC	L 3.5
Hgb	L 10.4
Hct	L 31.3
MCV	88.4
MCH	29.4
MCHC	33.2
RDW-CV	13.7
Platelet	185
MPV	H 11.4
Absolute Neutrophil count Auto# (ANC)	H 10.7
Lymphocyte Auto #	1.6
Monocyte Auto #	H 1.2
Eosinophil Auto #	0.0
Basophil Auto #	0.04
Neutrophil Auto %	78.8
Lymphocyte Auto %	11.8
Monocyte Auto %	9.1
Eosinophil Auto %	0.0
Basophil Auto %	0.3

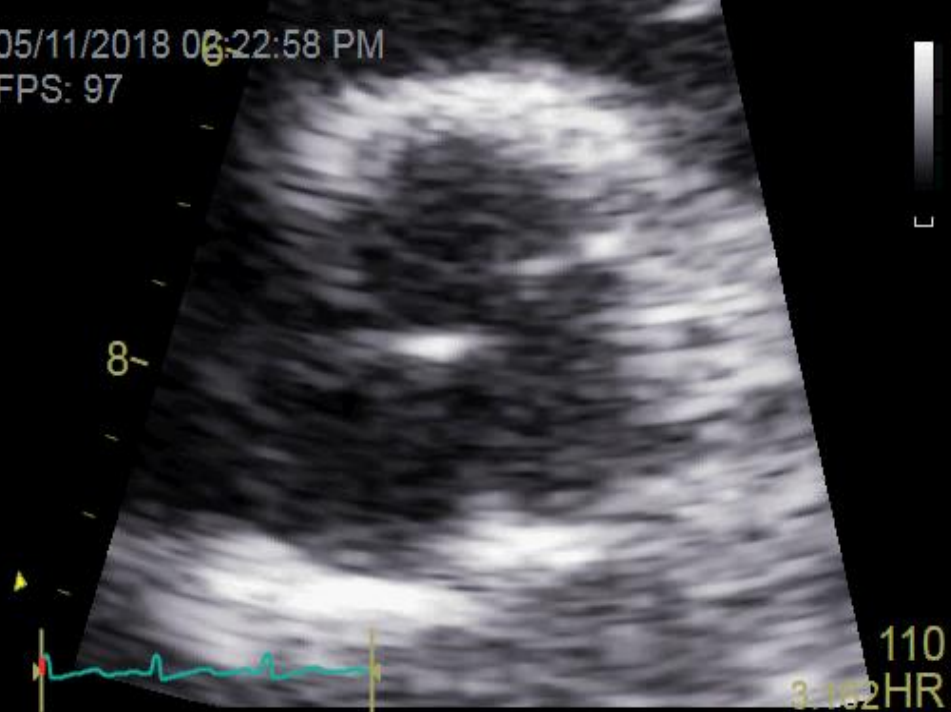
Coagulation	
Prothrombin Time	H 12.9
INR	1.2
Fibrinogen	
APTT	* L 24.3
General Chemistry	
Urea	H 26.40
Creatinine	H 200
eGFR	
Sodium	H 147
Potassium.	4.4
Chloride	H 110
Bicarbonate	23
Calcium	L 1.98
Calcium Corr	2.30
Phosphorus	H 1.58
Magnesium.	H 1.14
Bilirubin T	5
Bilirubin D	
Total Protein	68
Albumin	L 23.8
Alk Phos	114
ALT	H 46
AST	31
CK	
Glu Random	
Glucose	* H 11.2
HbA1C %	
Haptoglobin	
CRP	* H 47.2
Procalcitonin	* 0.54

- LP consistent with bacterial meningitis
Blood cultures grew MRSA
Nasal positive MRSA
Resp. viral panel negative

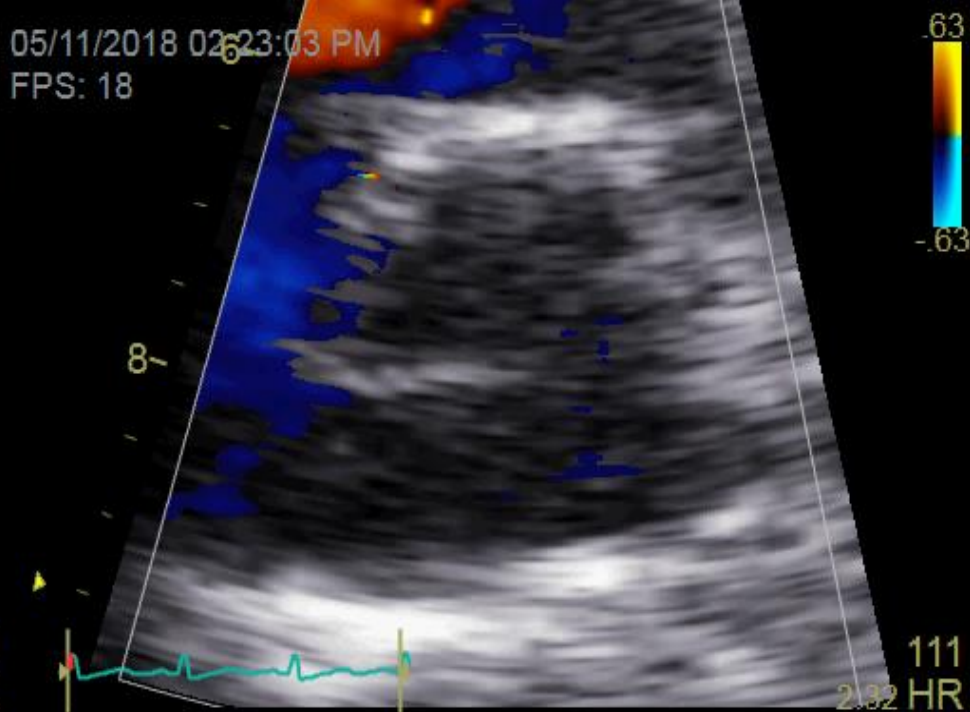
echo



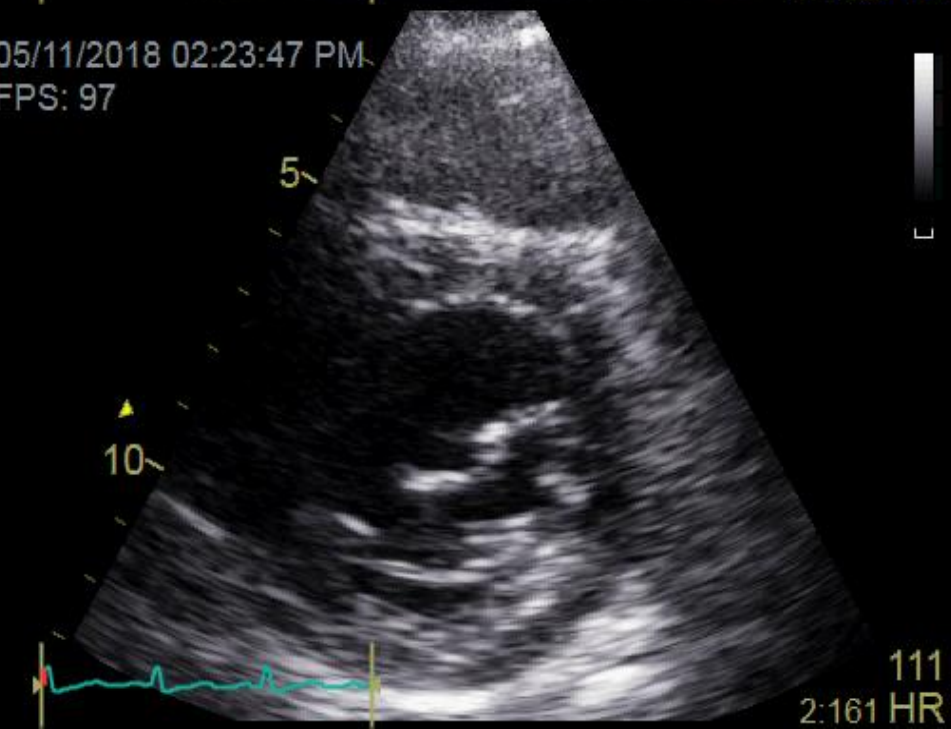
05/11/2018 02:22:58 PM
FPS: 97



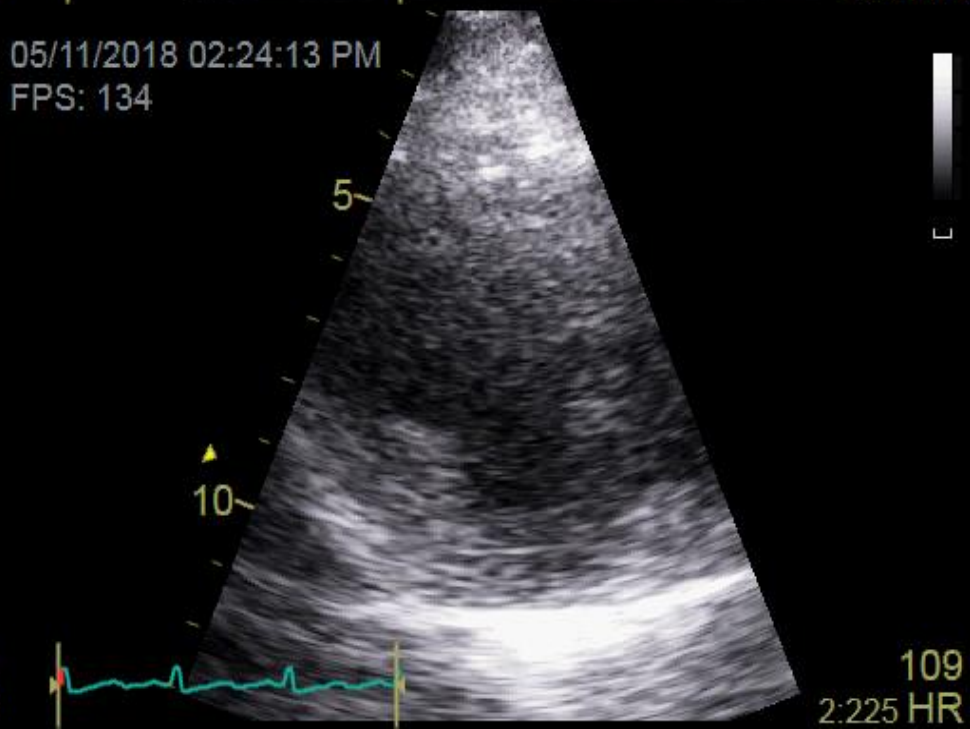
05/11/2018 02:23:03 PM
FPS: 18

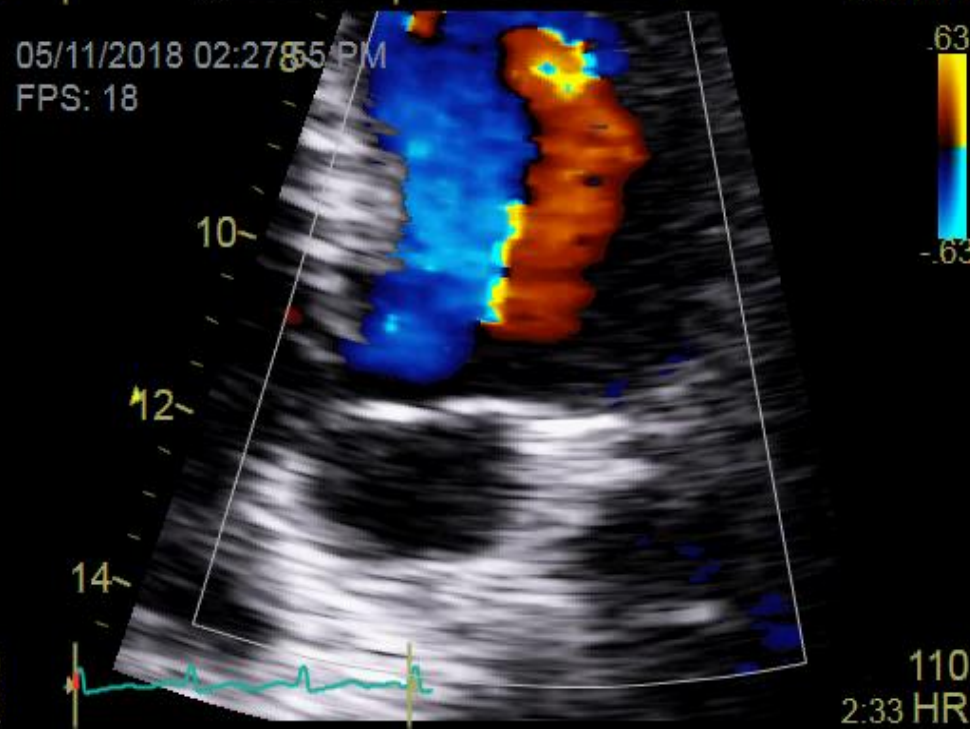
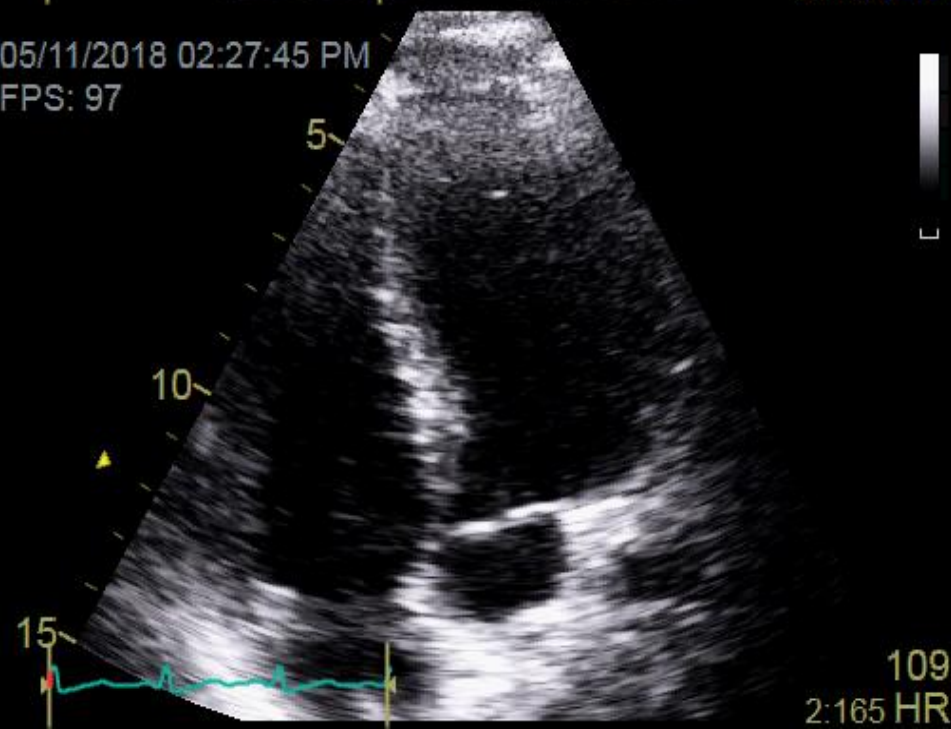
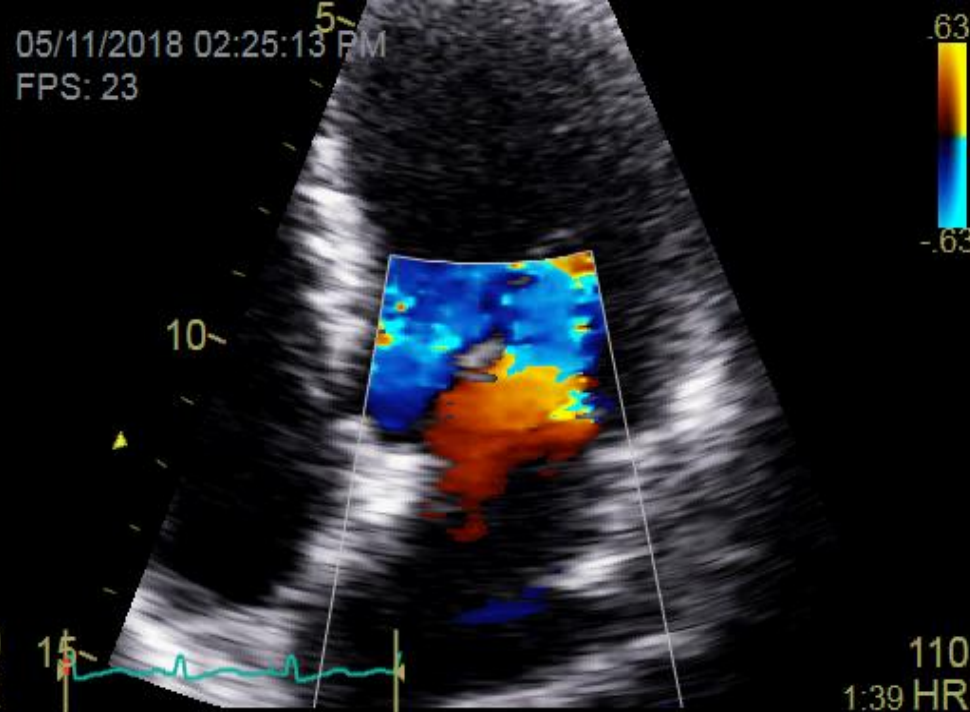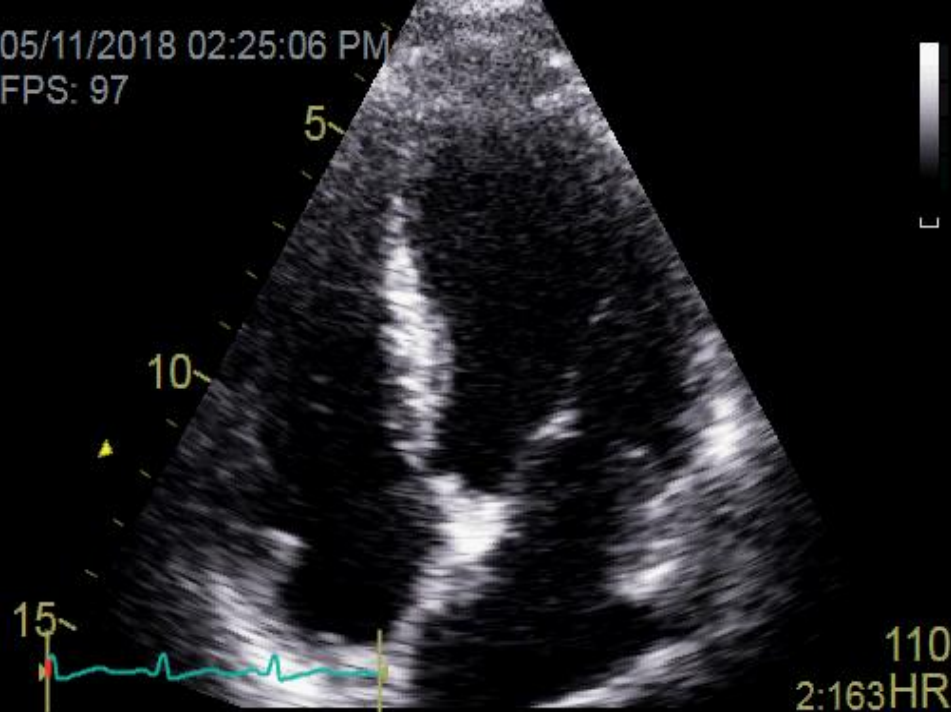


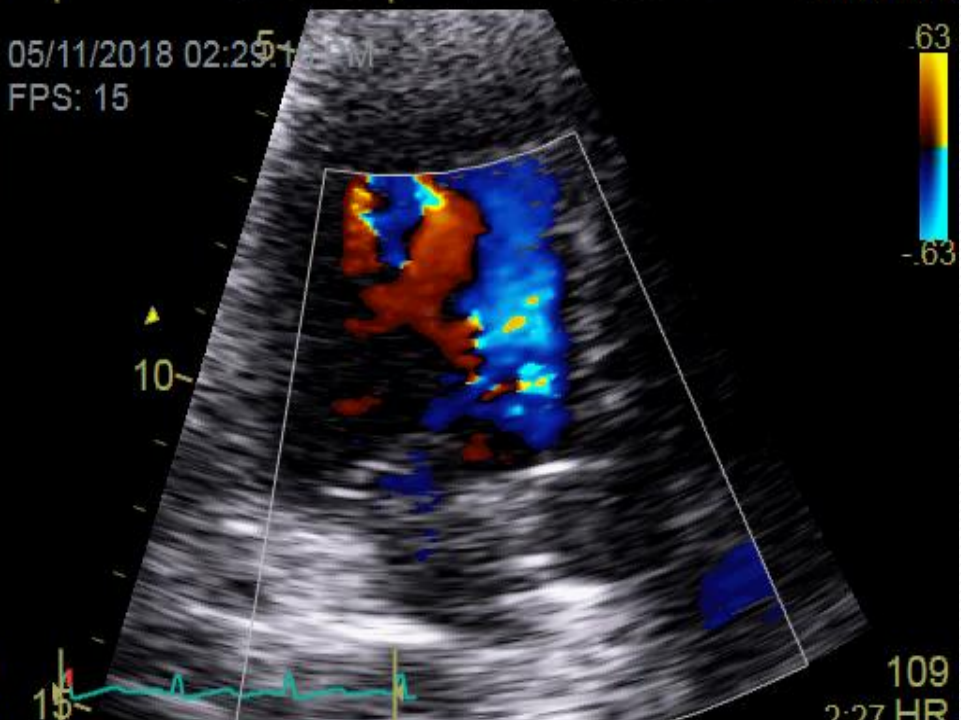
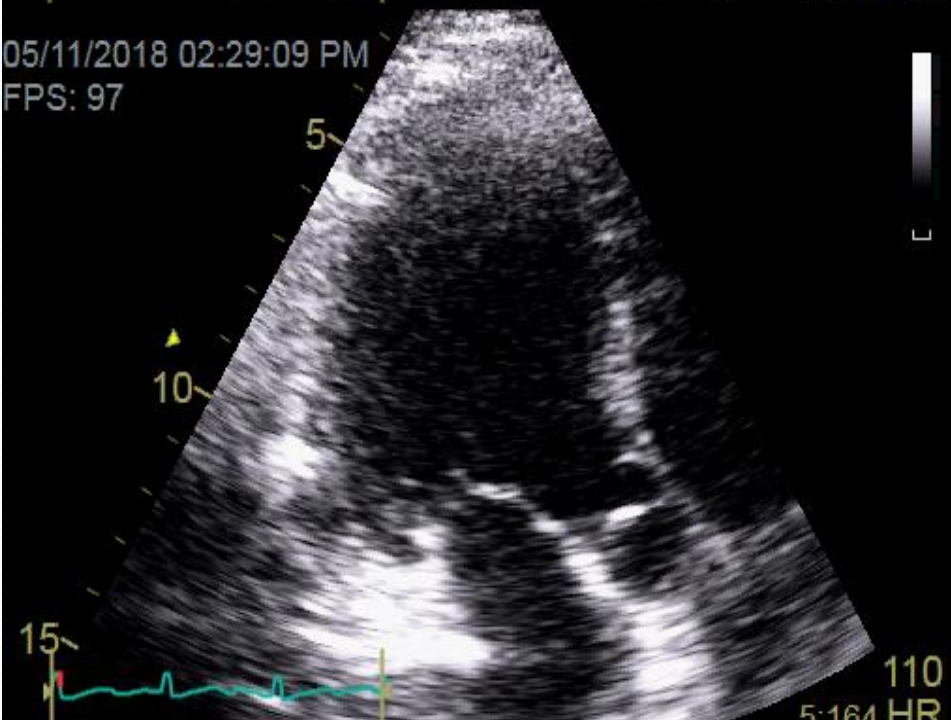
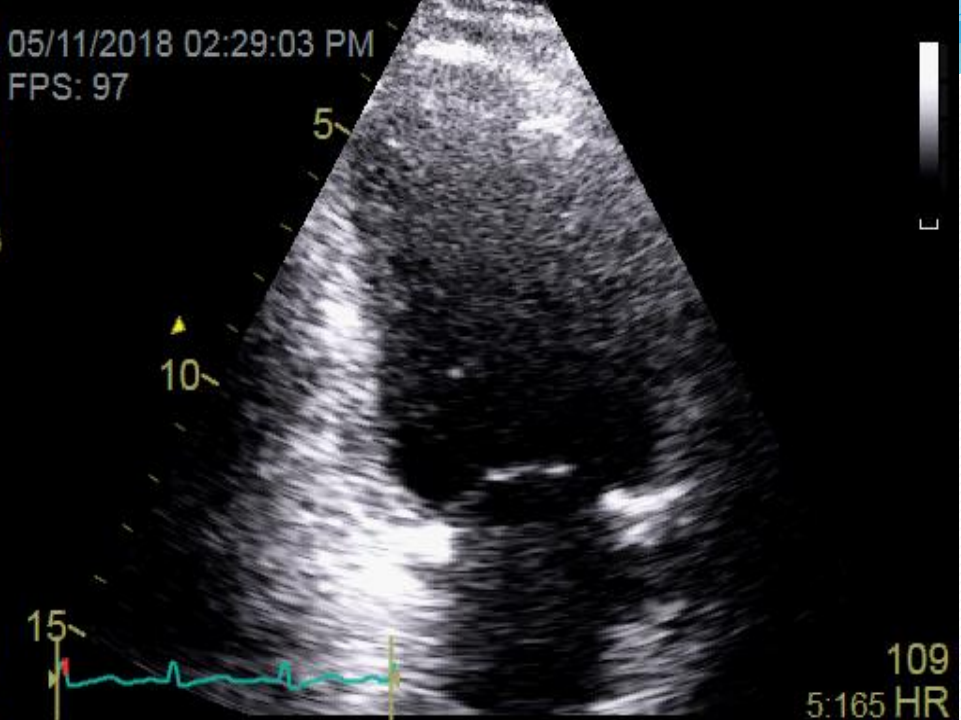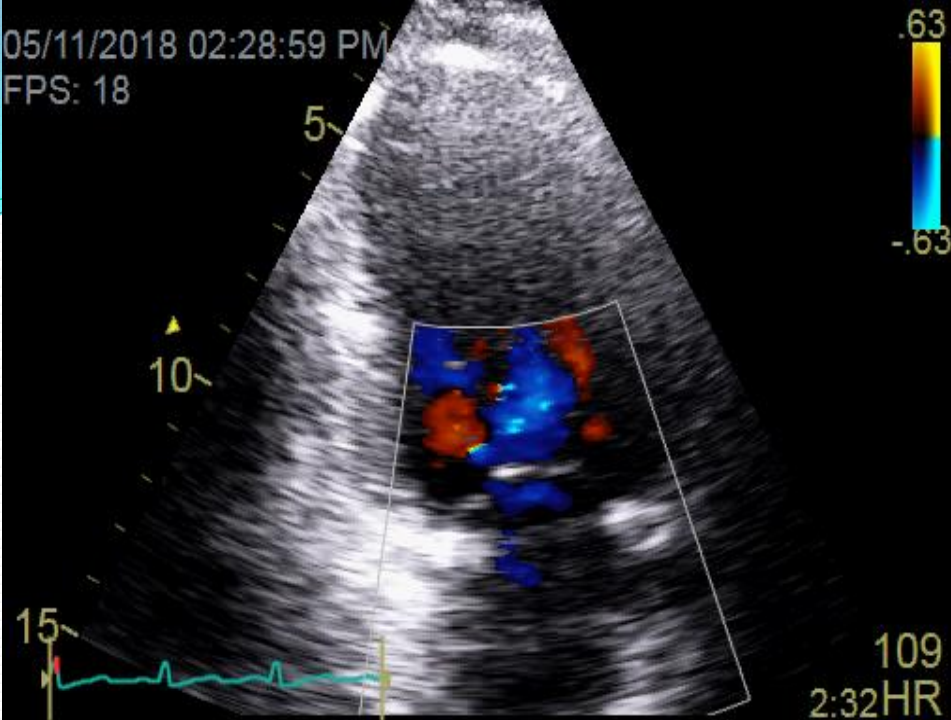
05/11/2018 02:23:47 PM
FPS: 97



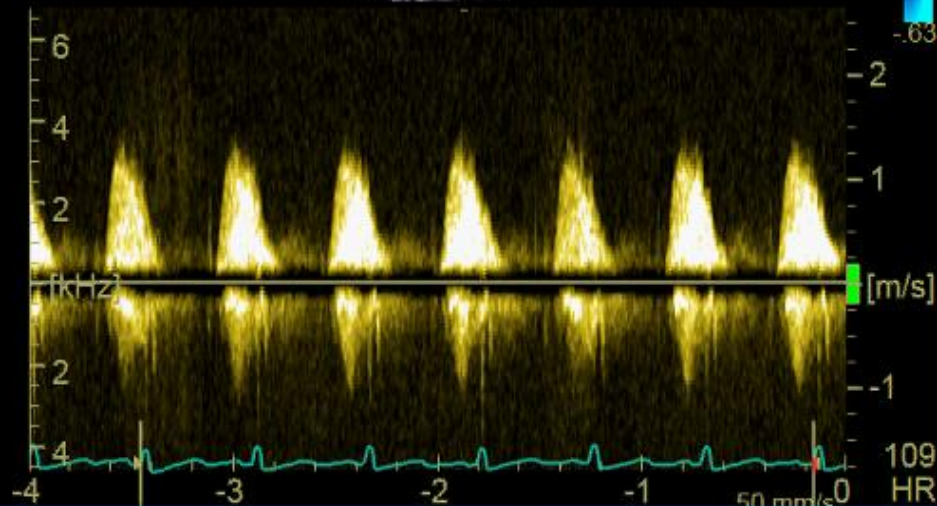
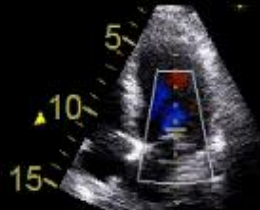05/11/2018 02:24:13 PM
FPS: 134



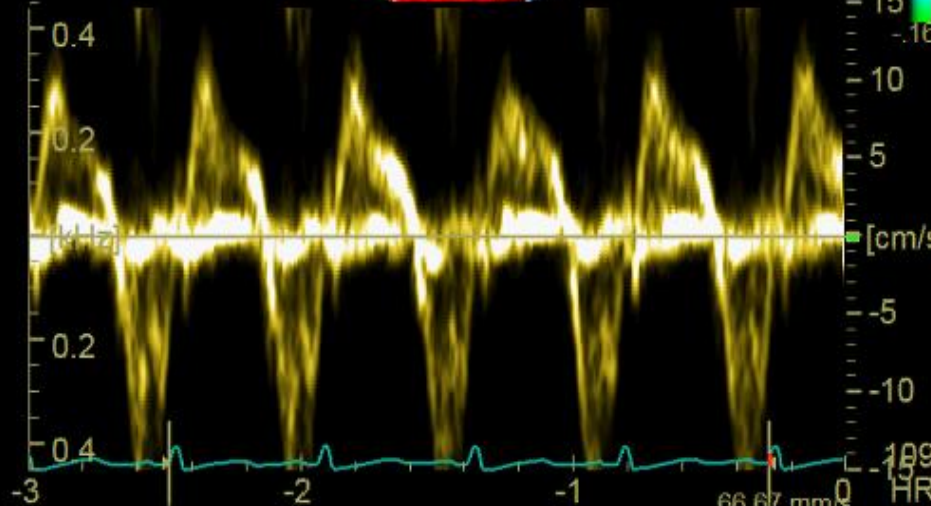
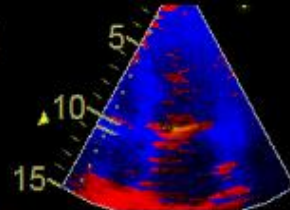




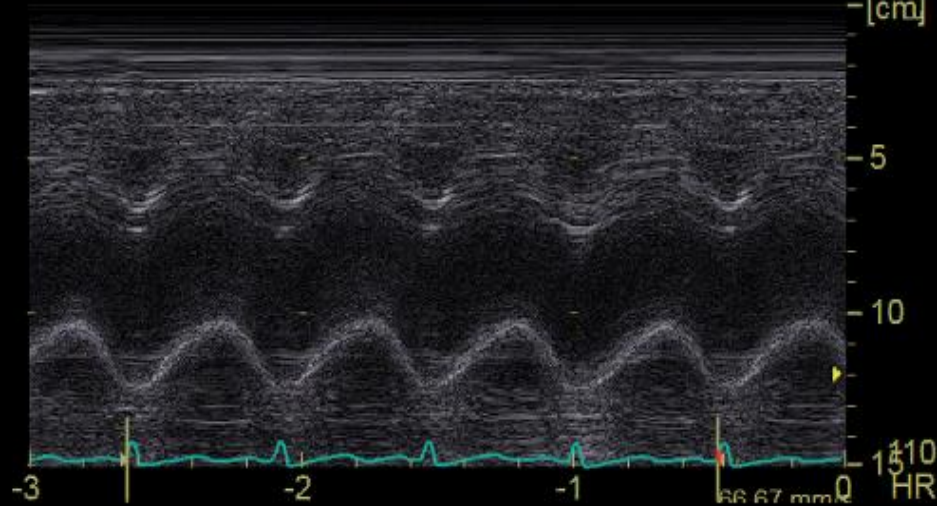
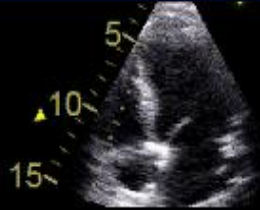
05/11/2018 02:25:51 PM
FPS: 23



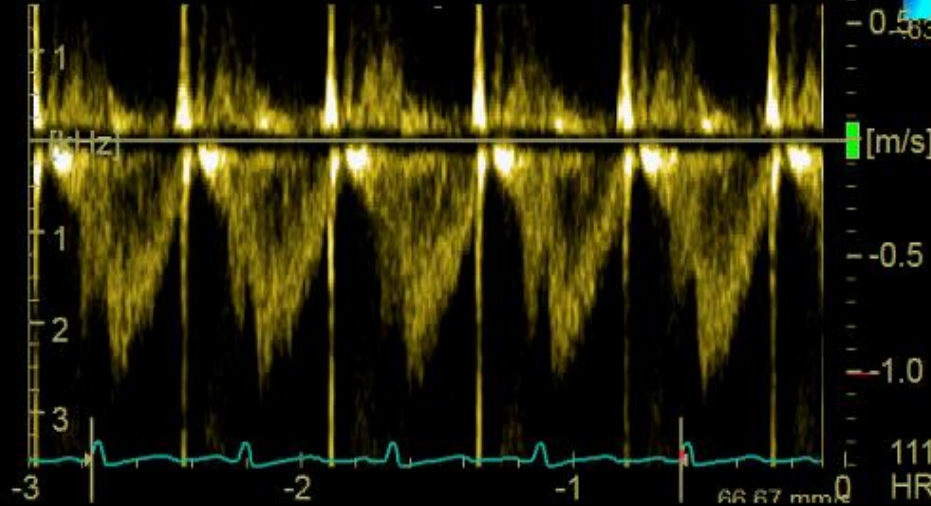
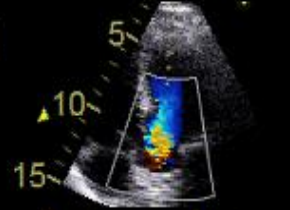
05/11/2018 02:26:55 PM
FPS: 34/101



05/11/2018 02:27:00 PM
FPS: 48



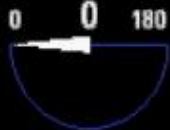05/11/2018 02:28:07 PM
FPS: 18



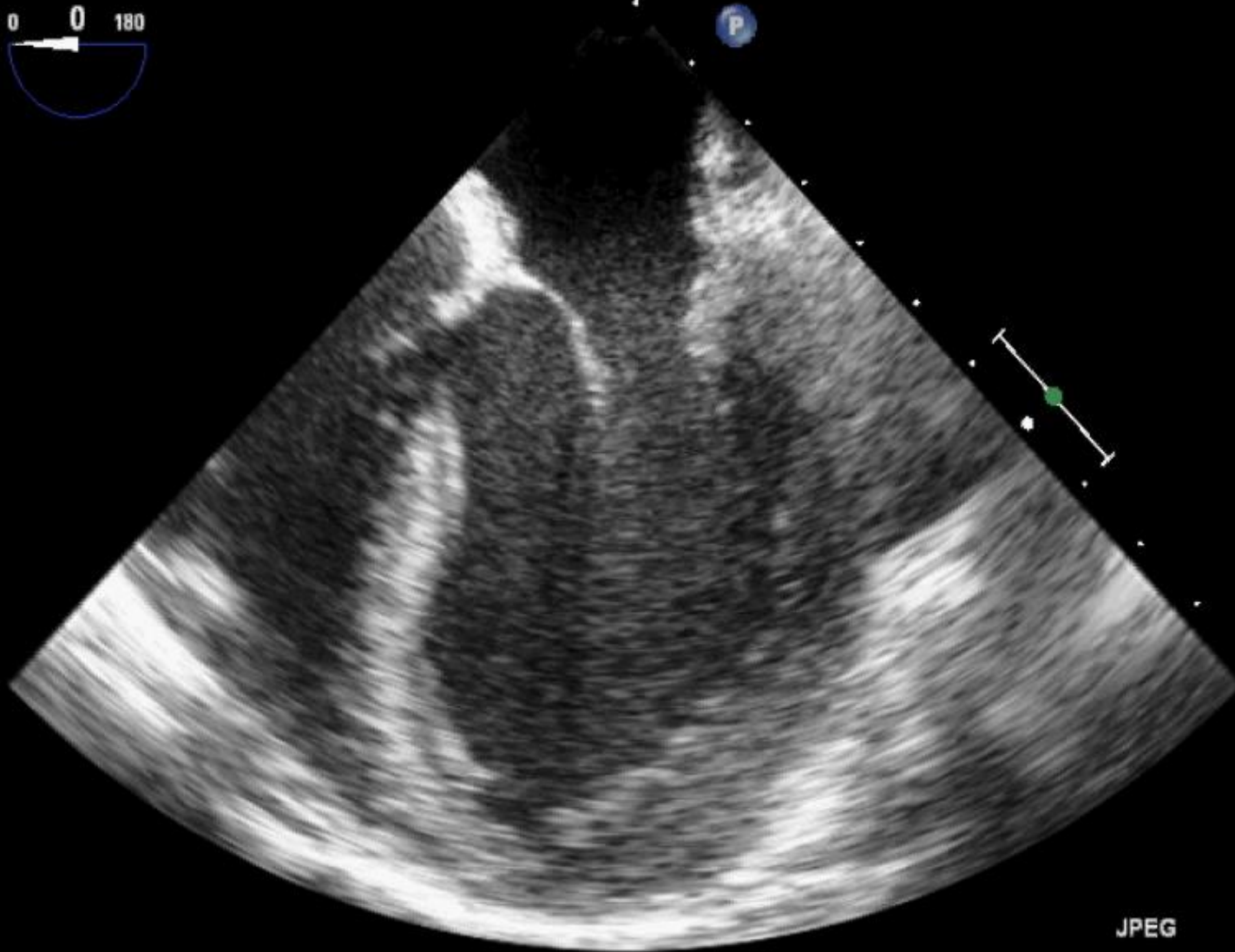
- 
- The patient was extubated in MICU and then TEE is advised

FR 35Hz
11cm

2D
72%
C 50
P Off
Gen



M4



JPEG

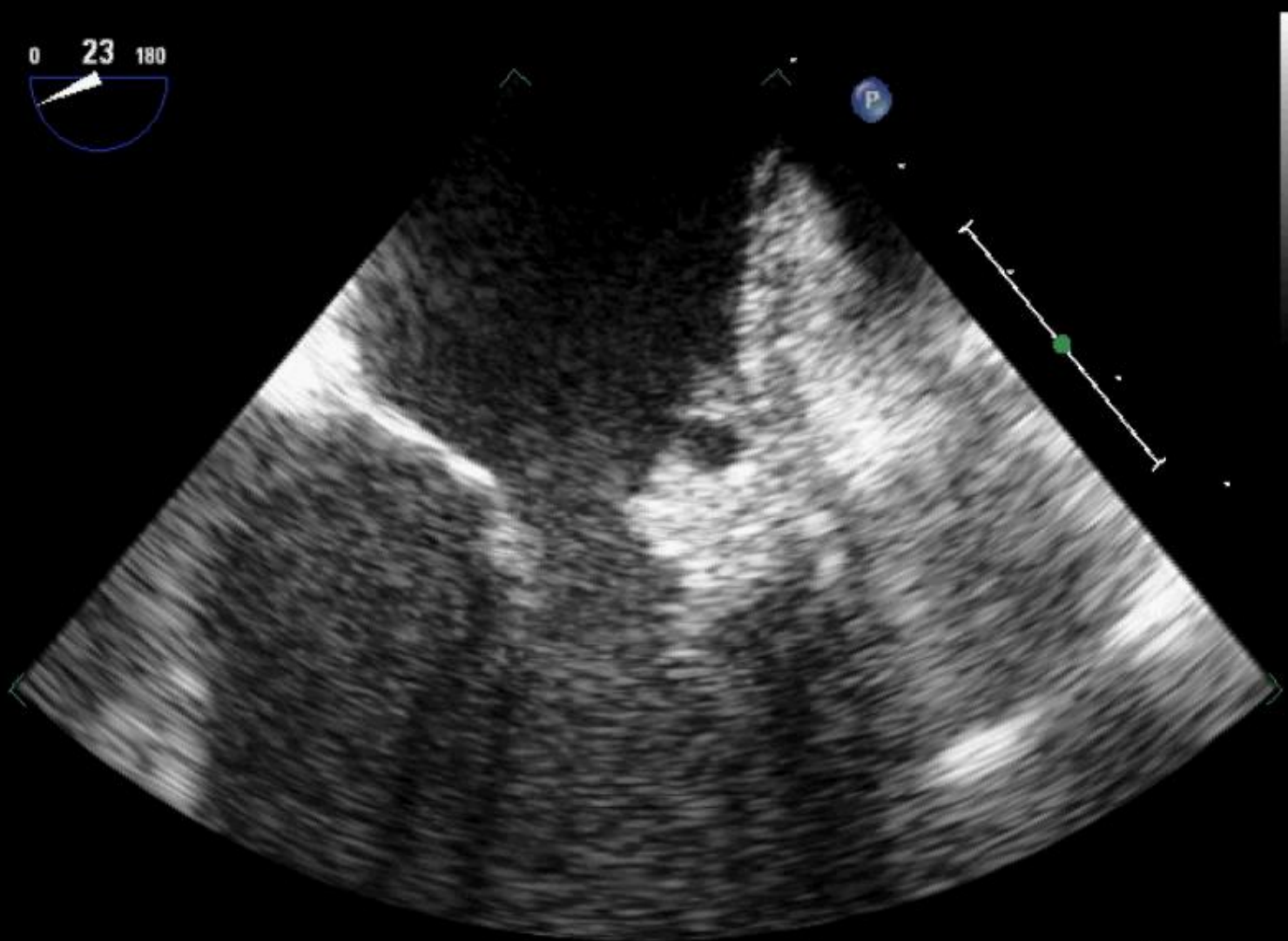
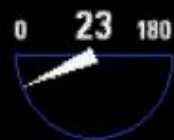PAT T: 37.0C
TEE T: 35.9C

74 bpm

FR 37Hz
6.3cm

M4

2D
72%
C 50
P Off
Gen



JPEG

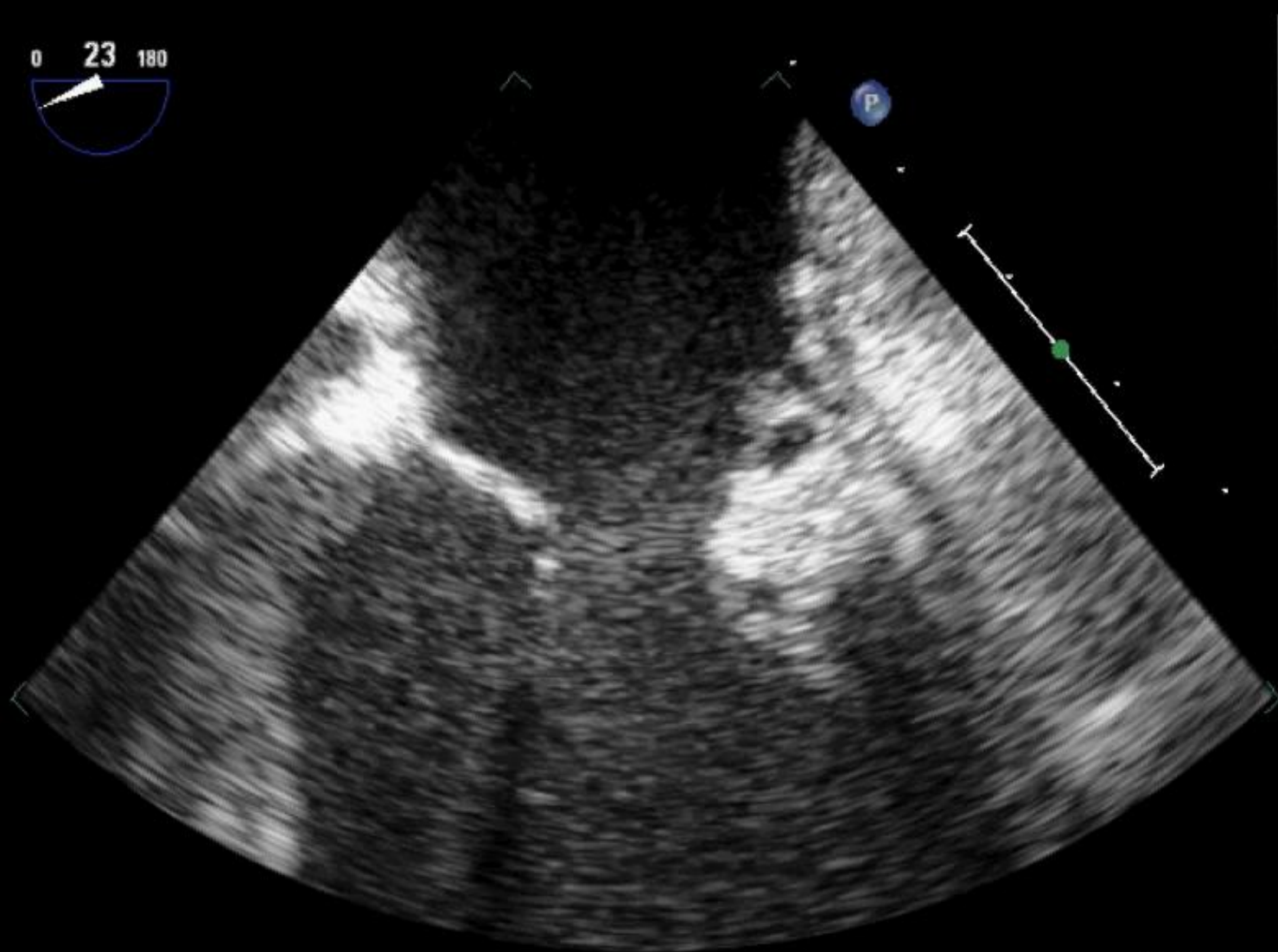
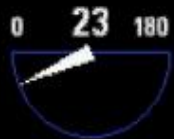PAT T: 37.0C
TEE T: 37.3C

74 bpm

FR 37Hz
6.3cm

M4

2D
72%
C 50
P Off
Gen



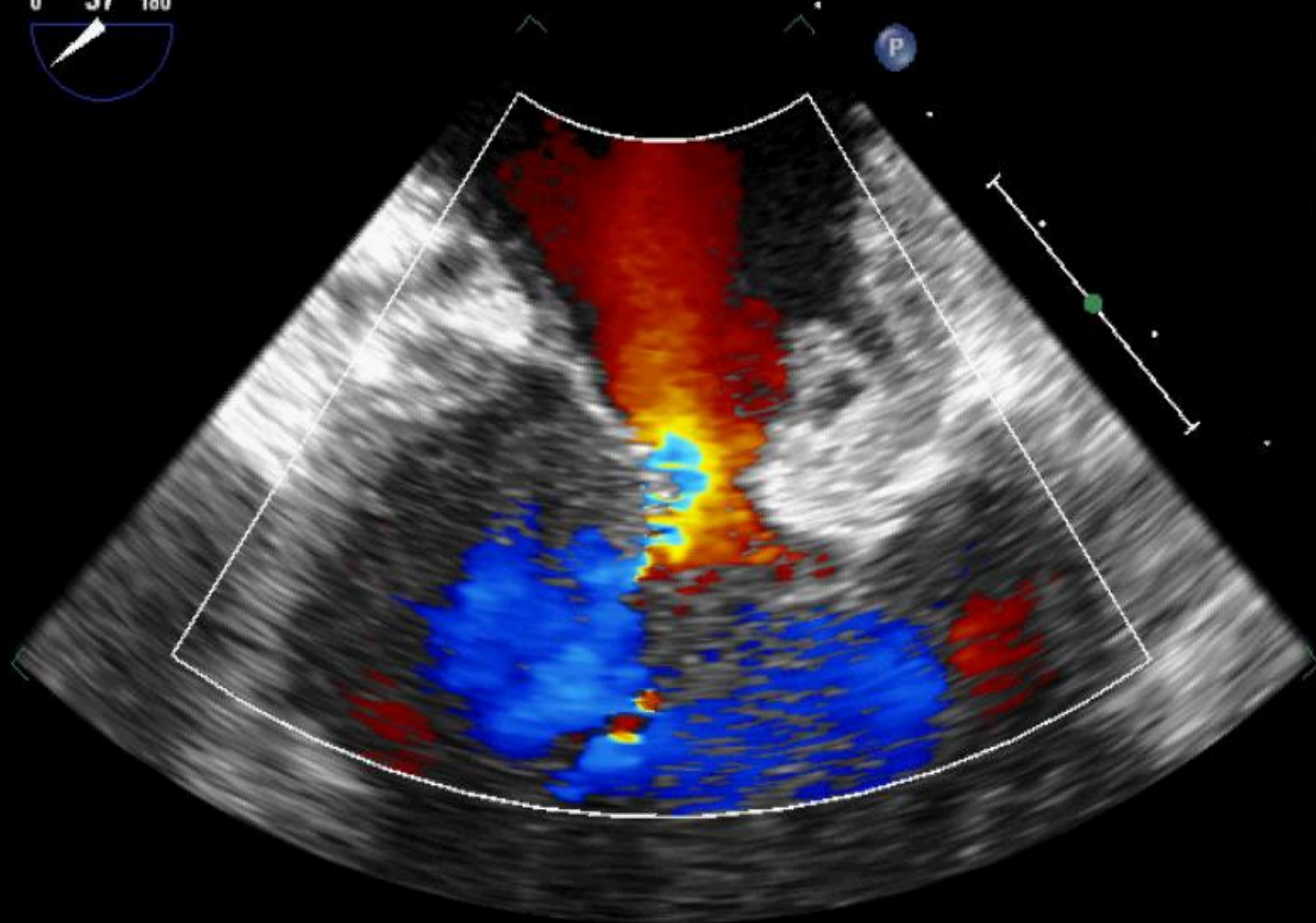
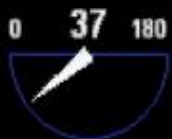JPEG

PAT T: 37.0C
TEE T: 37.5C

65 bpm

FR 12Hz
6.3cm

2D
75%
C 50
P Off
Gen
CF
63%
4.4MHz
WF High
Med



M4 M4
+61.6



-61.6
cm/s

JPEG

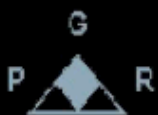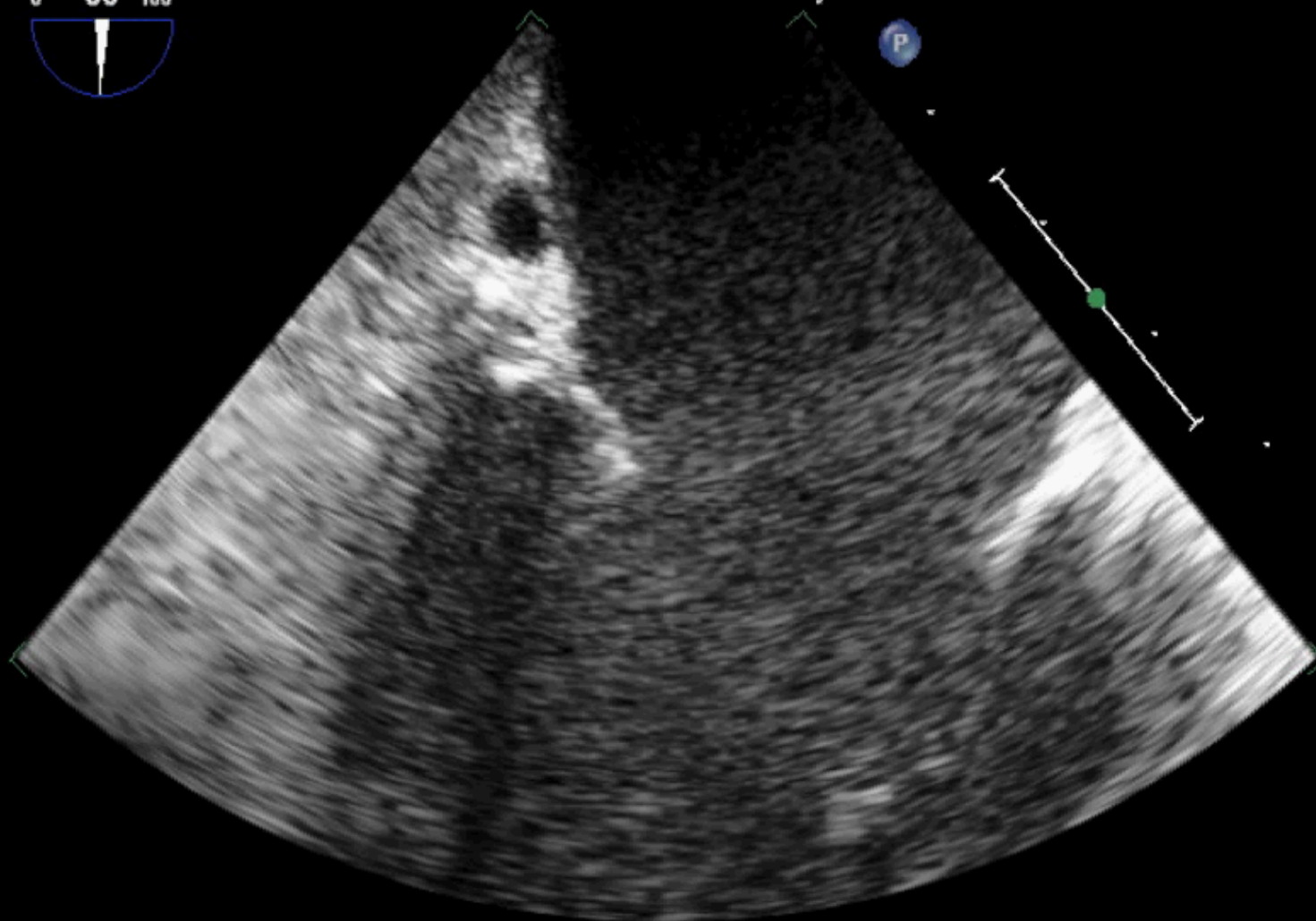
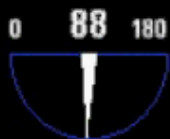PAT T: 37.0C
TEE T: 37.9C

47 bpm

FR 37Hz
6.3cm

M4

2D
72%
C 50
P Off
Gen



JPEG

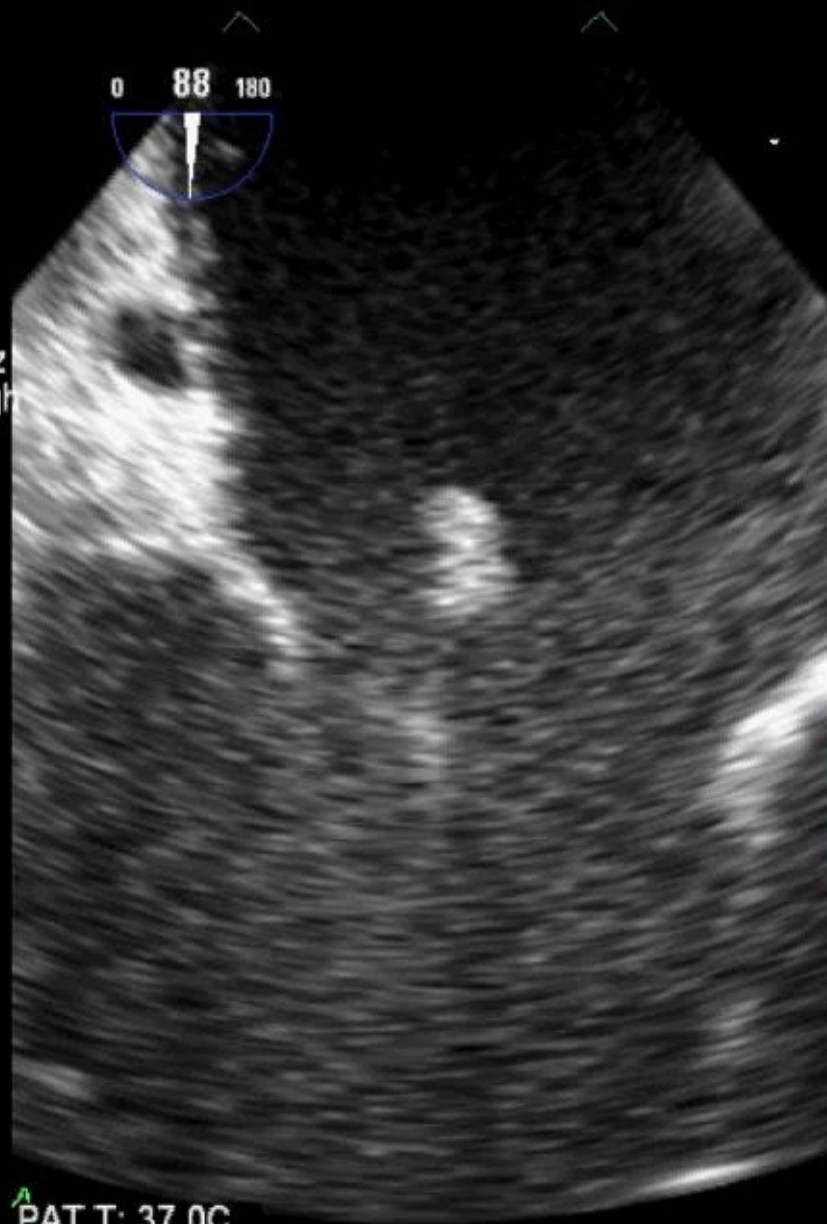
PAT T: 37.0C
TEE T: 38.1C

75 bpm

FR 11Hz
6.3cm

2D
75%
C 50
P Off
Gen
CF
63%
4.4MHz
WF High
Med

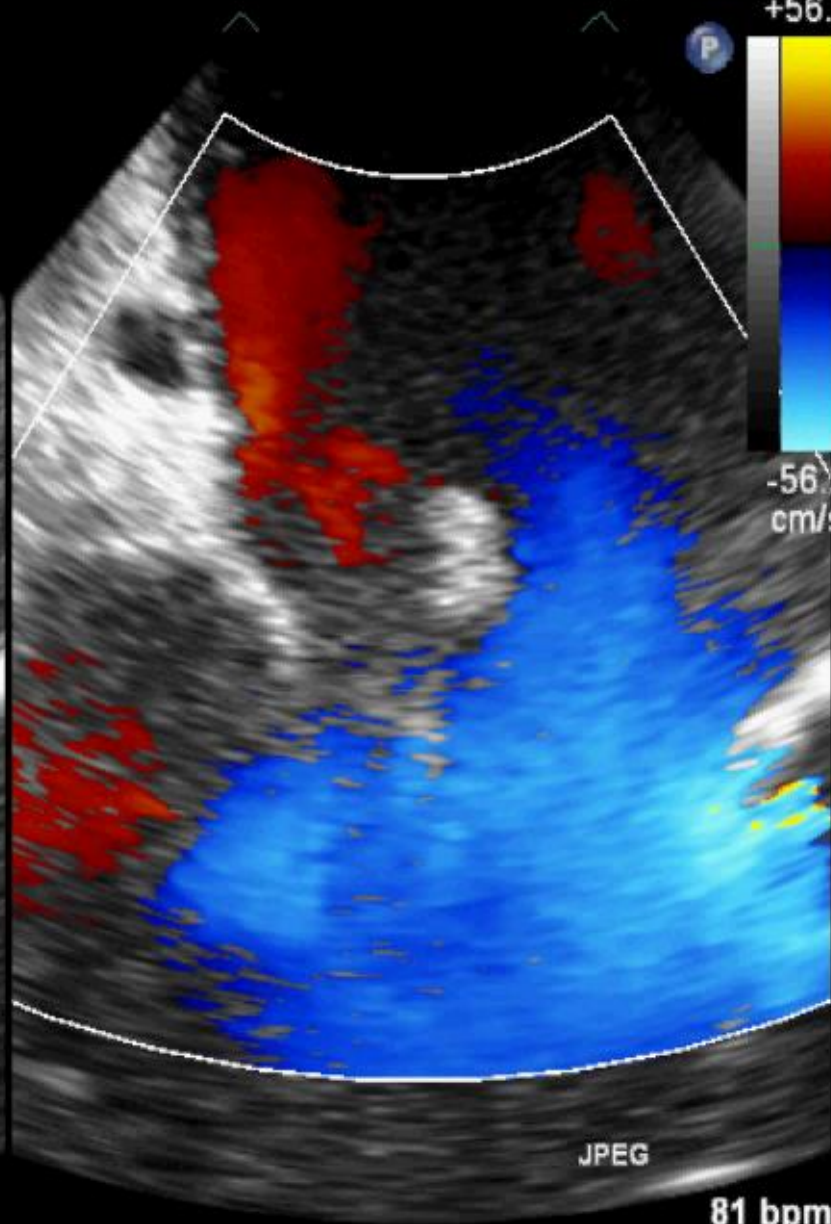
0 88 180



M4 M4
+56.2



-56.2
cm/s



JPEG

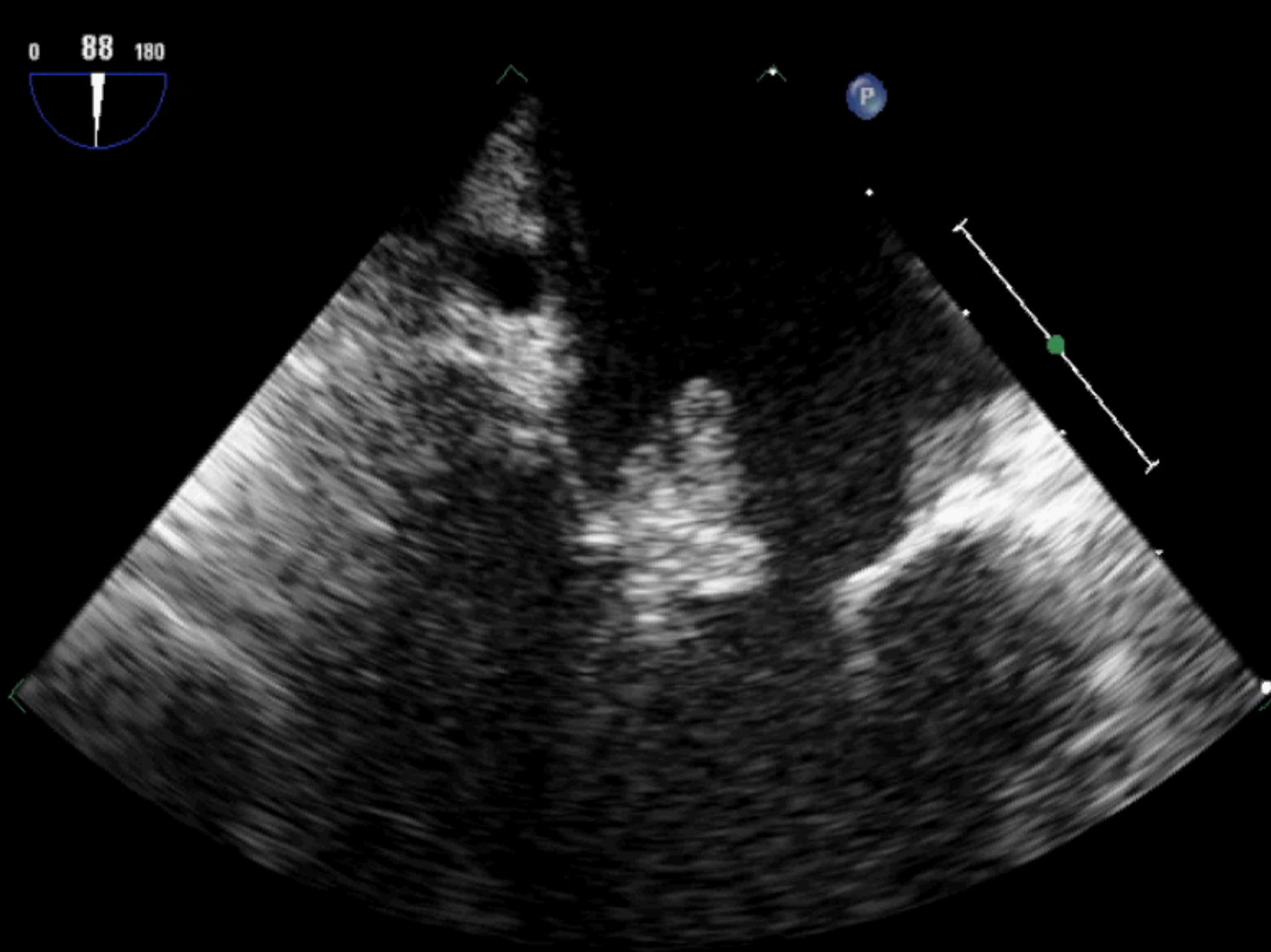
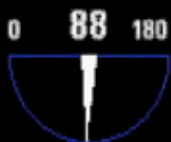PAT T: 37.0C

81 bpm

FR 37Hz
6.3cm

M4

2D
63%
C 44
P Off
Gen



JPEG

PAT T: 37.0C

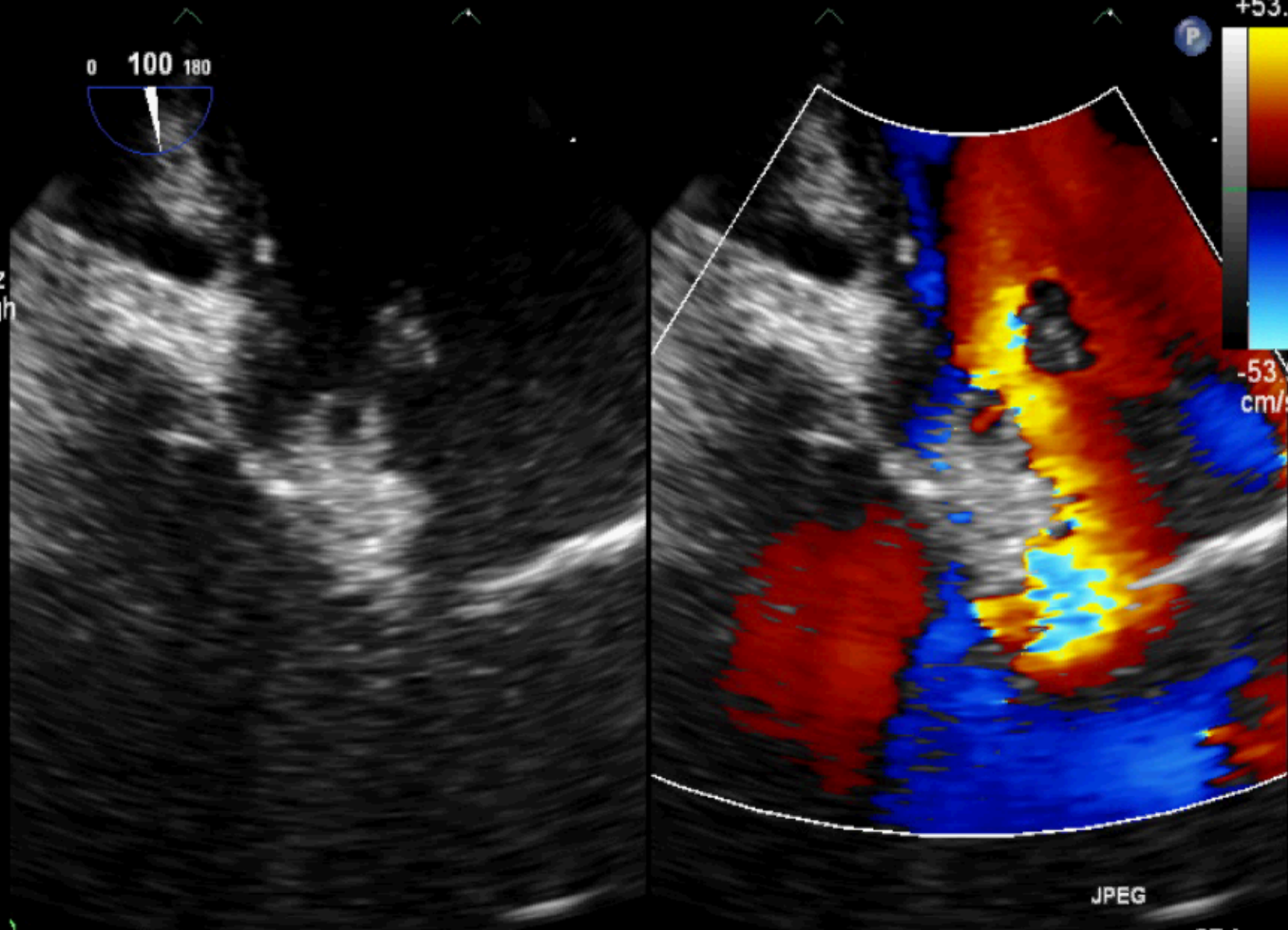
67 bpm

FR 11Hz
6.3cm

2D
66%
C 44
P Off
Gen
CF
63%
4.4MHz
WF High
Med



M4 M4
+53.9



JPEG

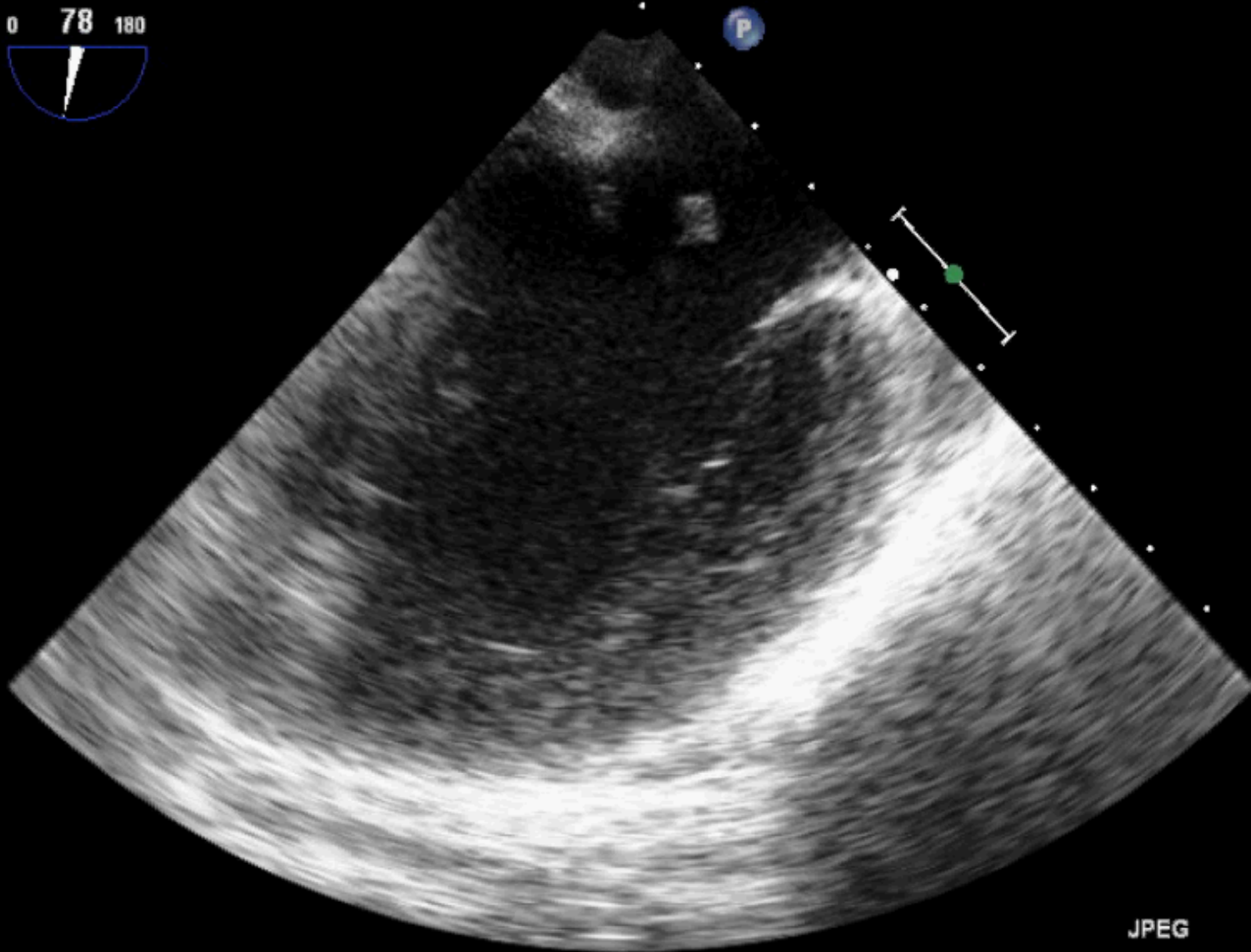
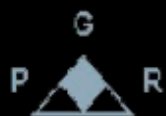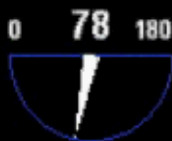PAT T: 37.0C

67 bpm

FR 35Hz
11cm

M4

2D
73%
C 44
P Off
Gen



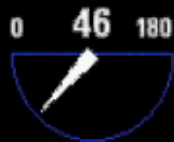JPEG

PAT T: 37.0C

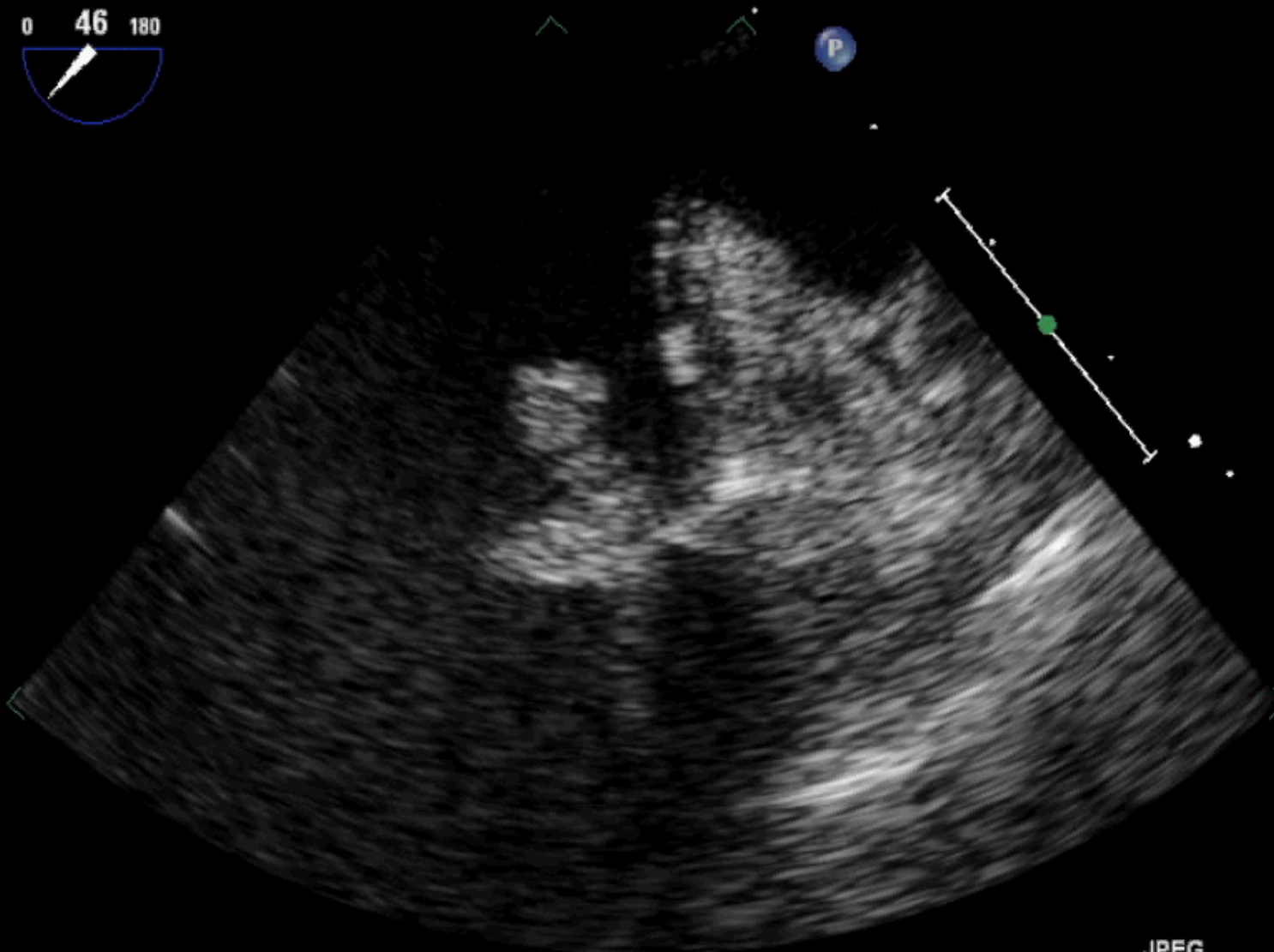
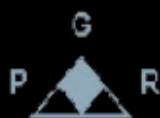79 bpm

PK 3/MZ
5.9cm

2D
68%
C 44
P Off
Gen



M4



JPEG

PAT T: 37.0C

83 bpm

FR 11Hz

6.7cm

2D

72%

C 45

P Off

Gen

CF

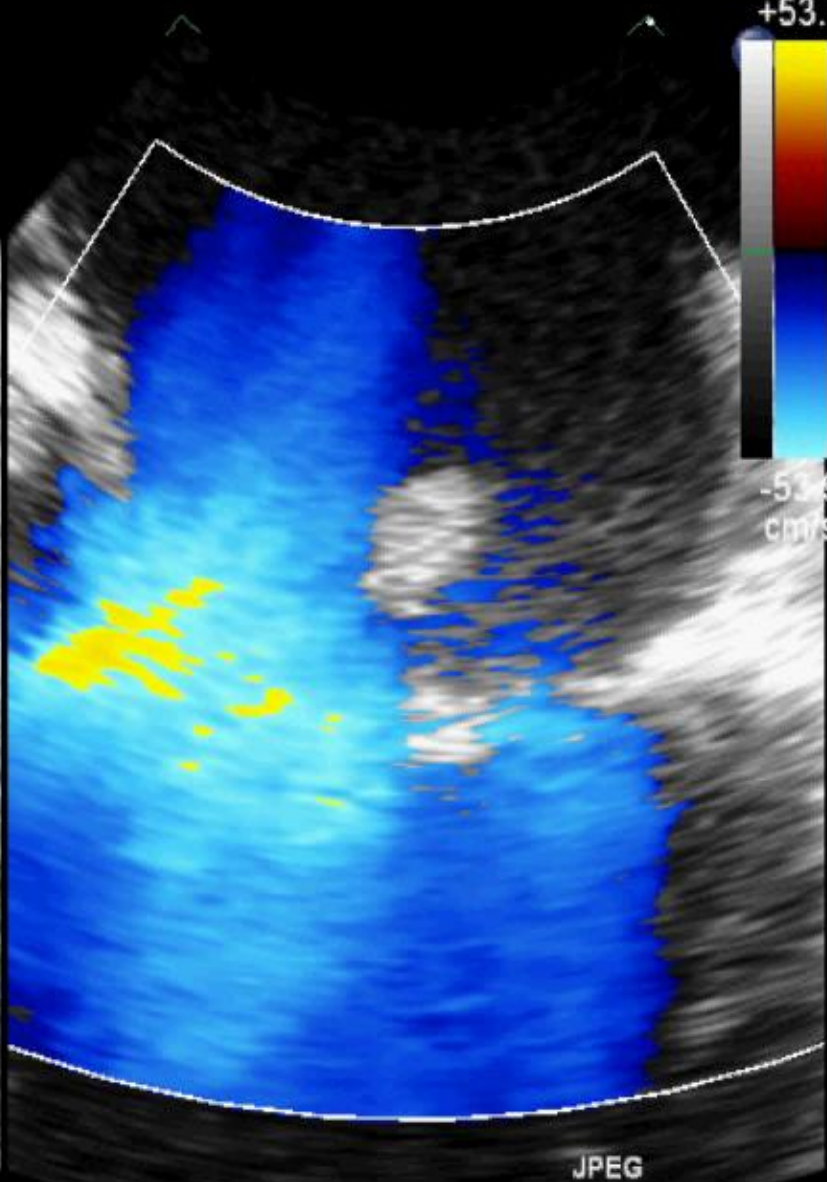
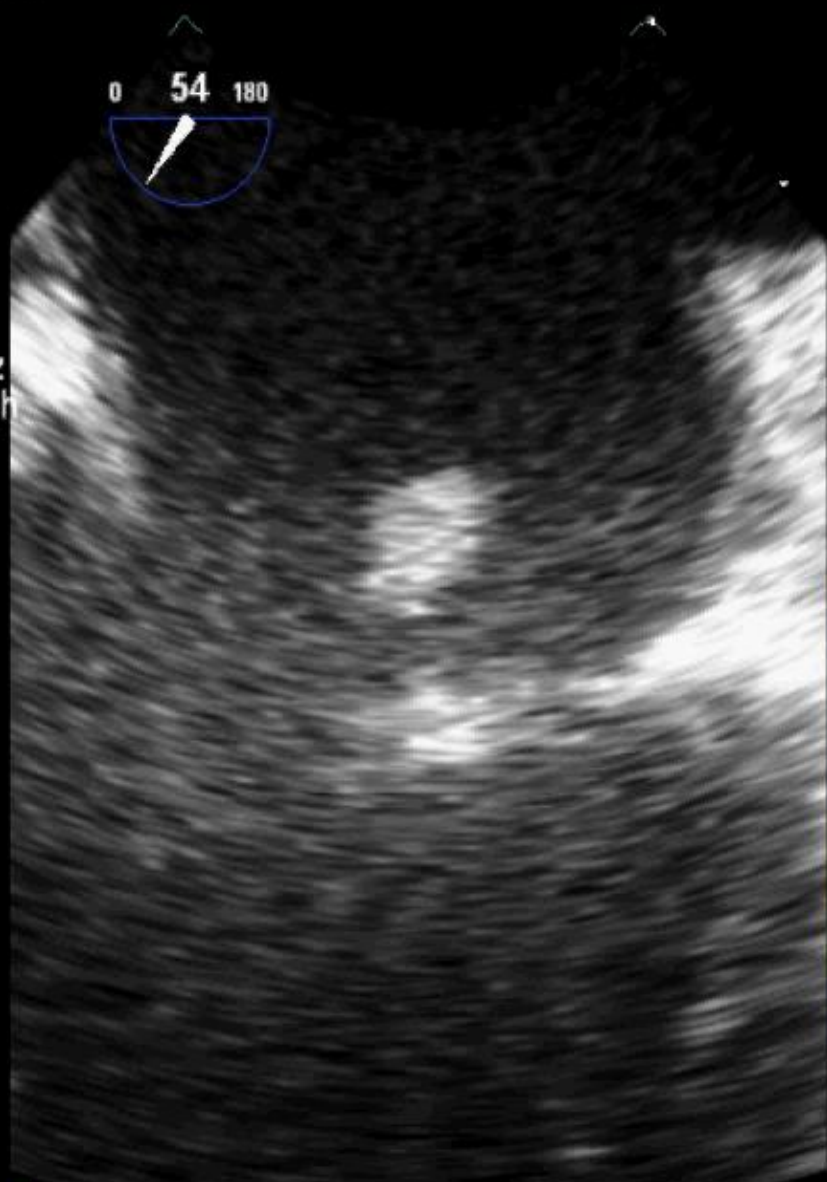
63%

4.4MHz

WF High

Med

0 54 180



M4 M4

+53.9



-53.9
cm/s

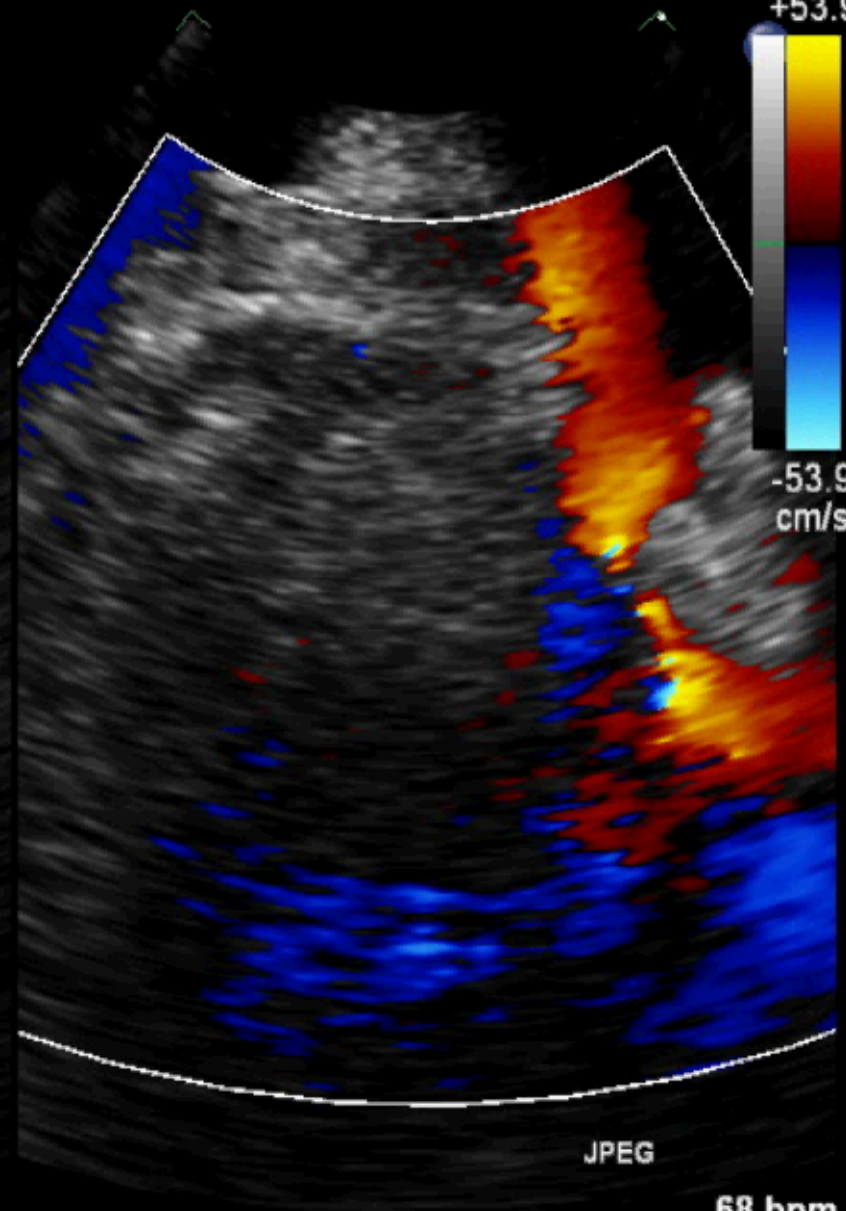
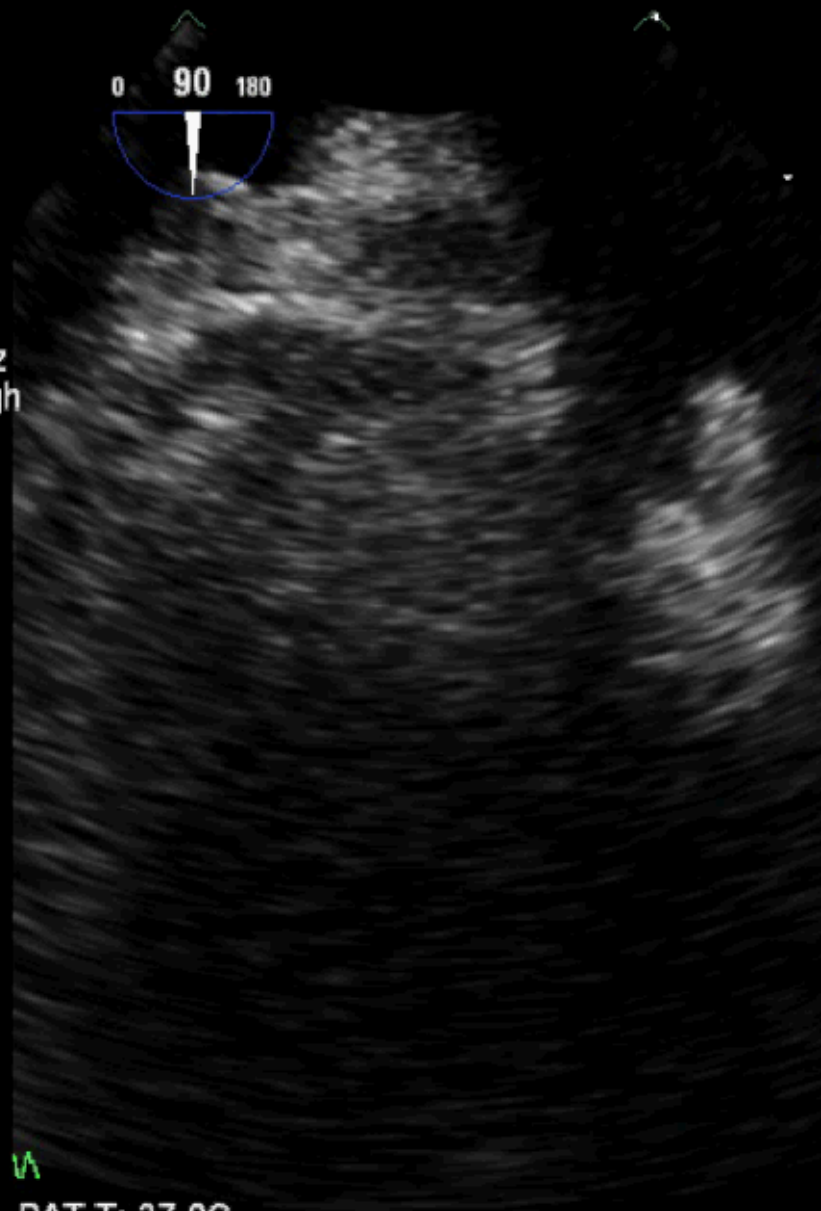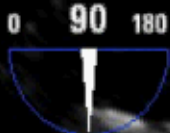JPEG

PAT T: 37.0C

69 bpm

FR 11Hz
6.7cm

2D
68%
C 45
P Off
Gen
CF
63%
4.4MHz
WF High
Med



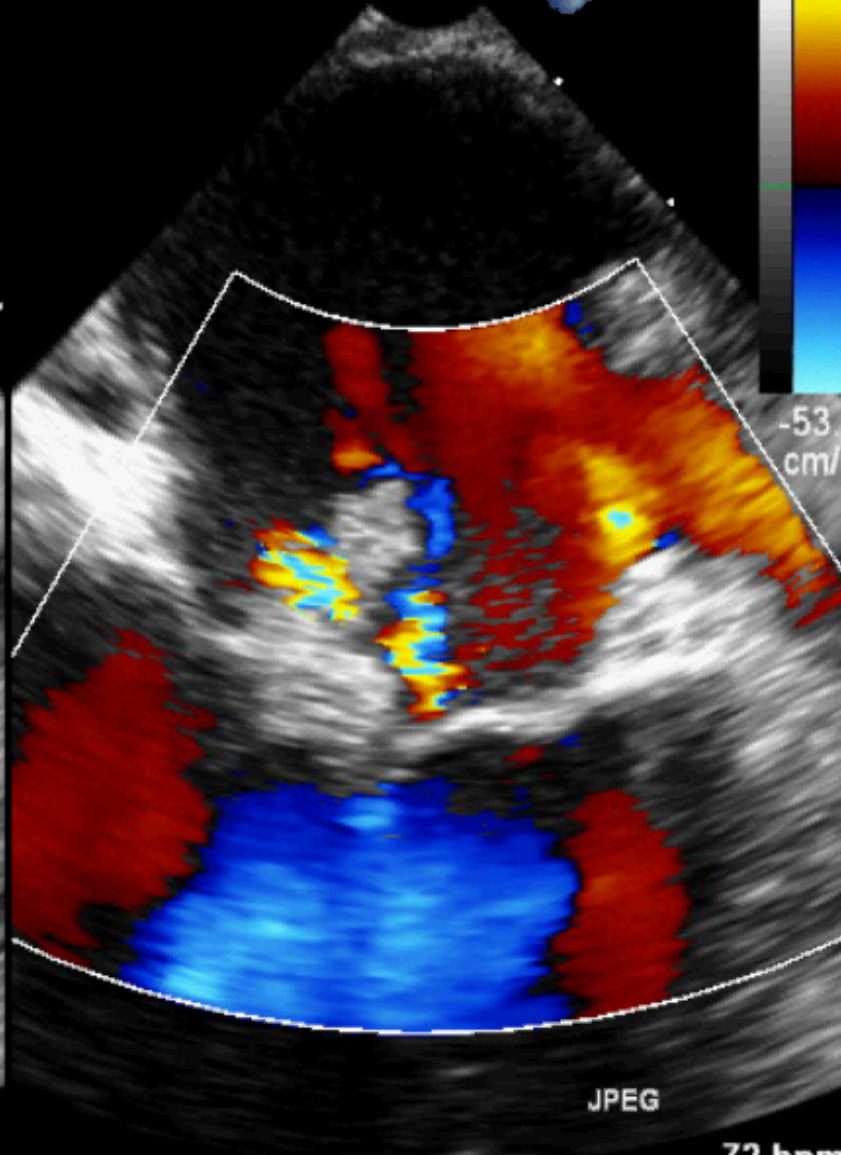
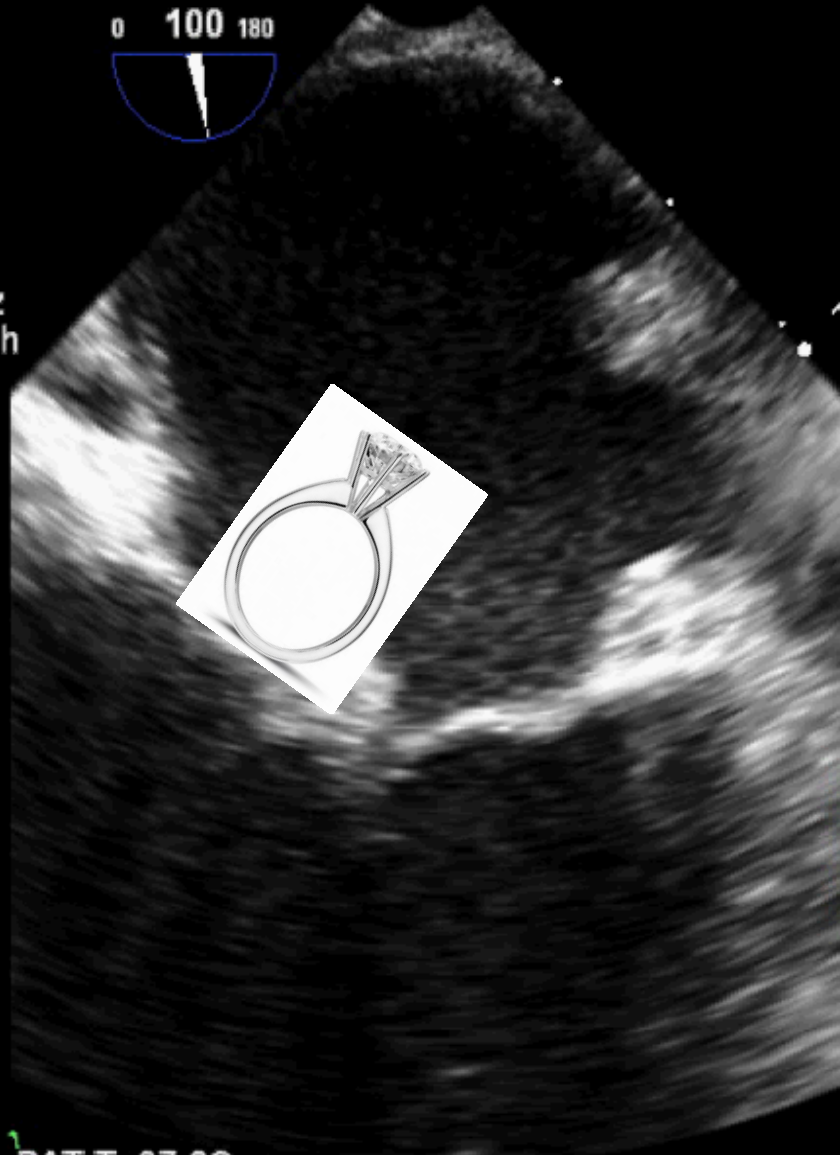
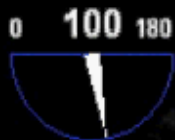V1
PAT T: 37.0C

JPEG

68 bpm

FR 11Hz
7.0cm

2D
66%
C 45
P Off
Gen
CF
63%
4.4MHz
WF High
Med



PAT T: 37.0C

72 bpm

- 
- Follow me with this

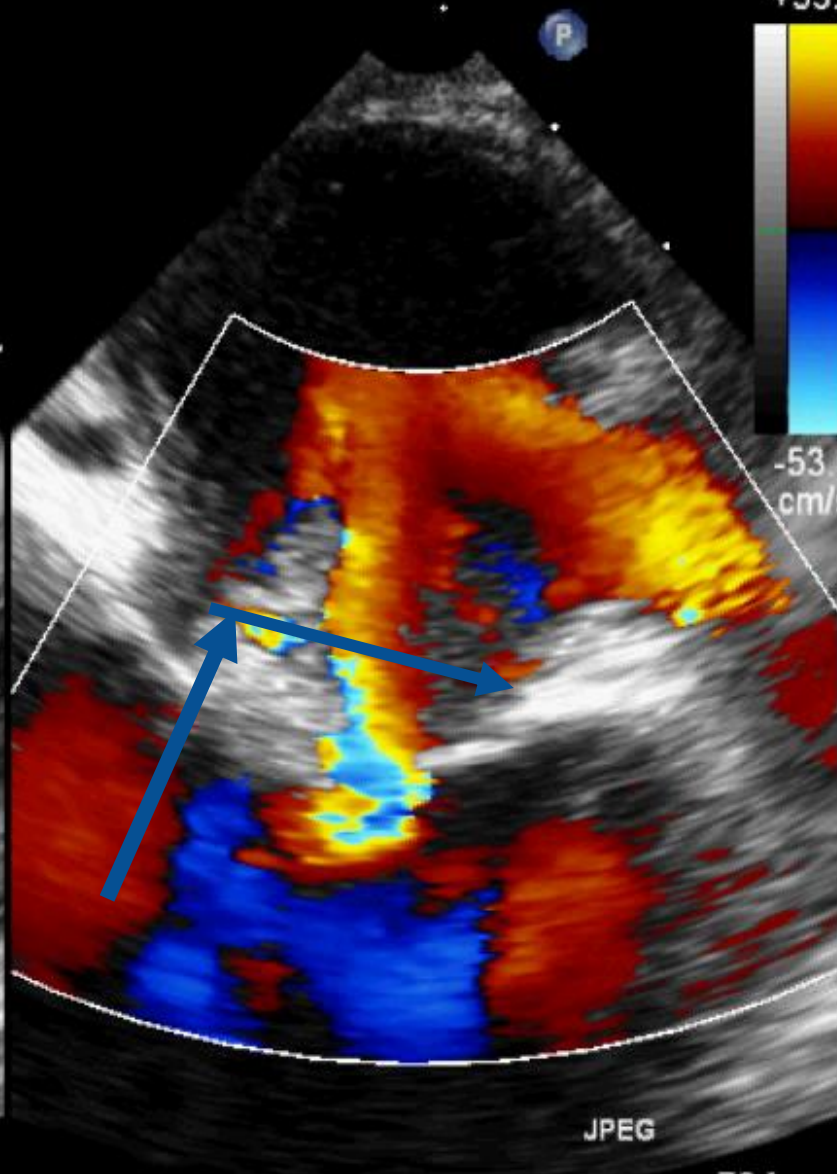
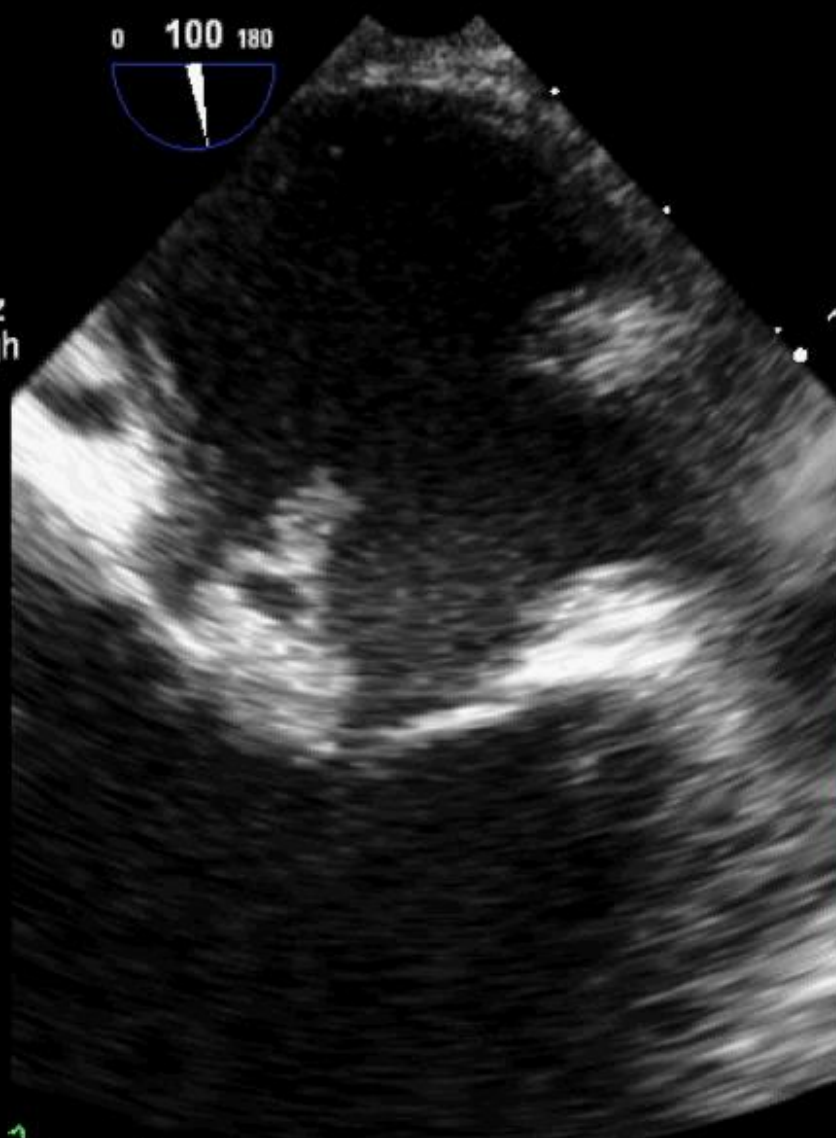
(a) Mitral Valve Leaflet

(b) Tricuspid Valve Leaflet



FR 11Hz
7.0cm


2D
66%
C 45
P Off
Gen
CF
63%
4.4MHz
WF High
Med

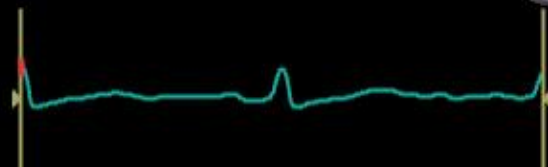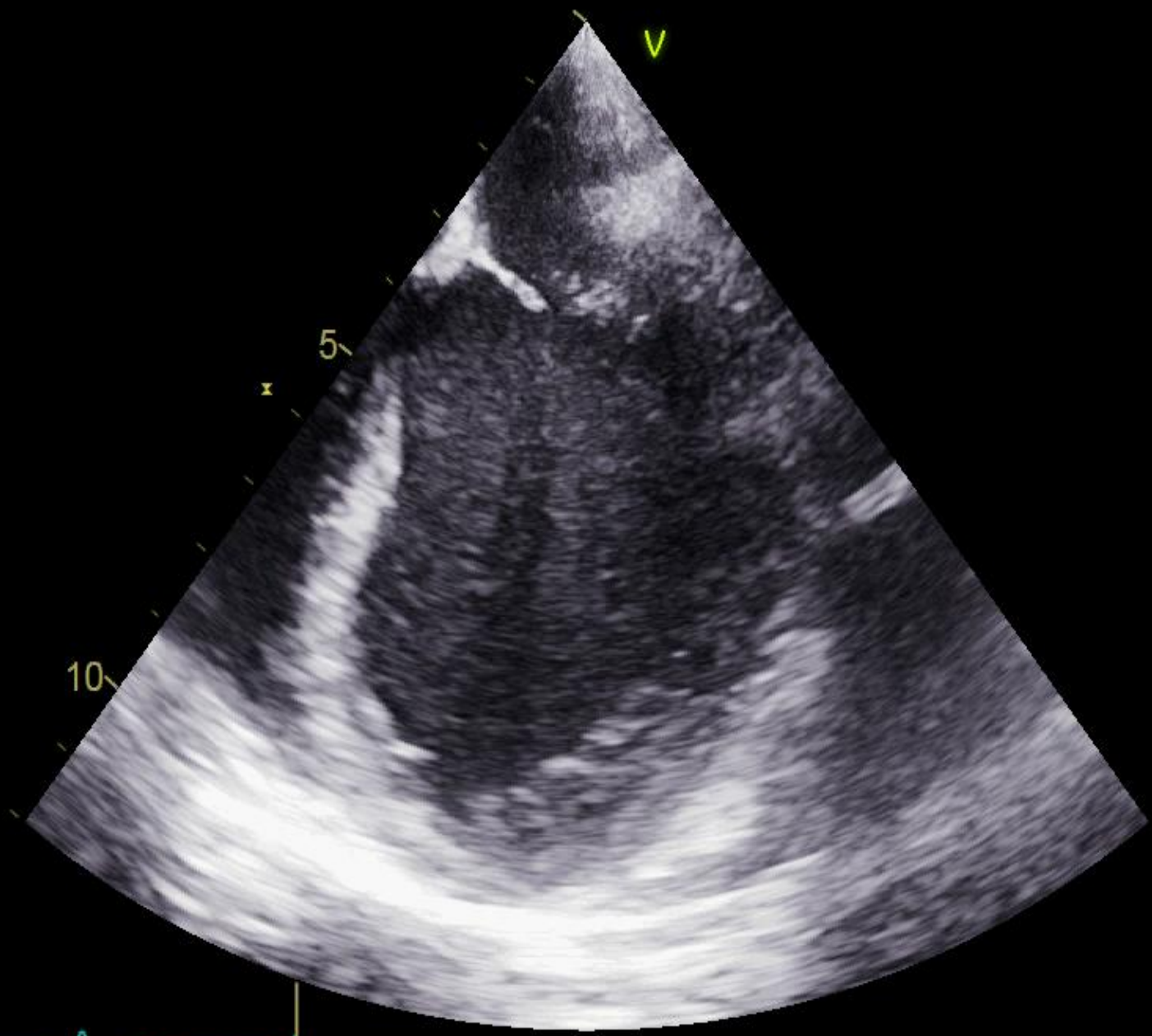


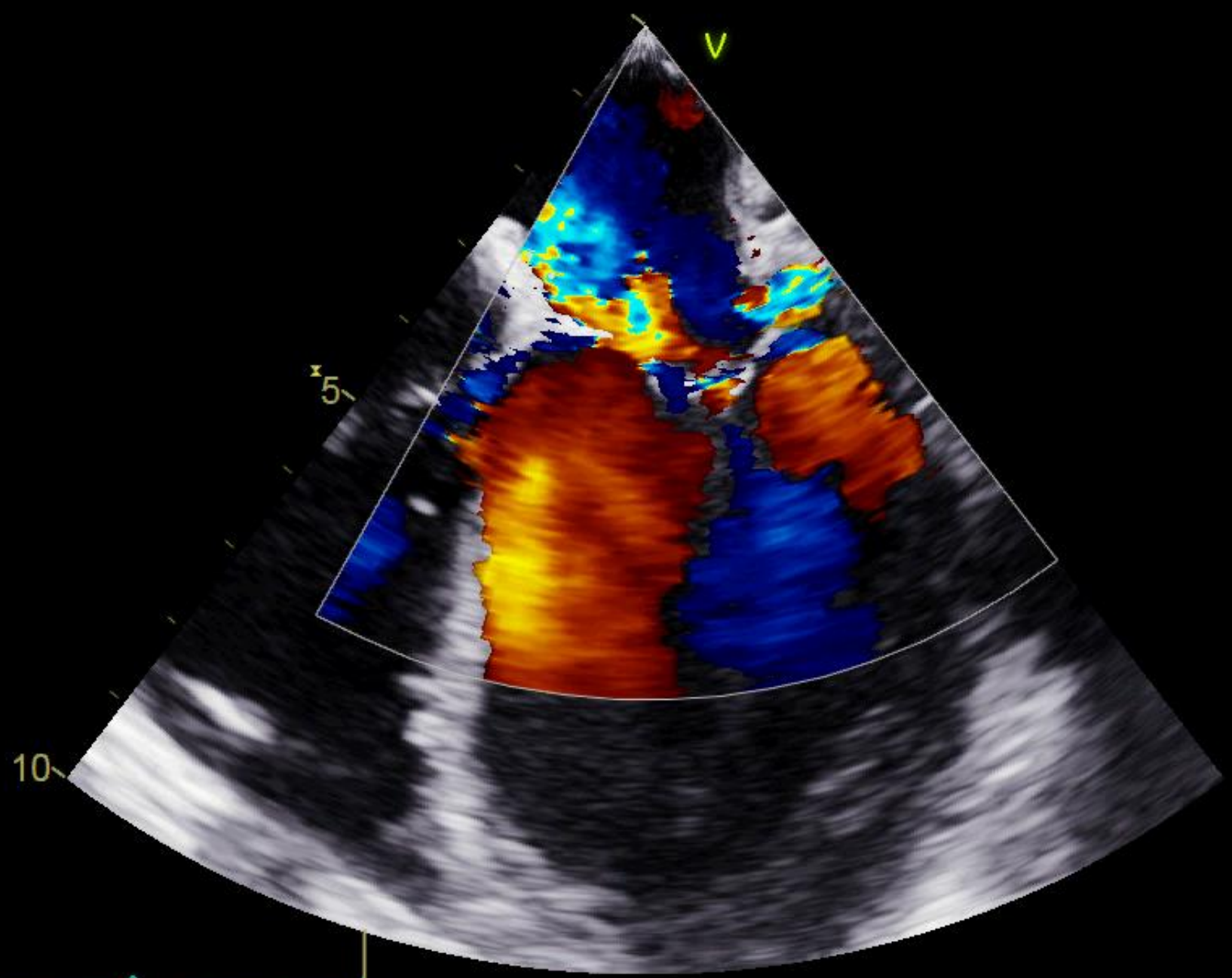
PAT T: 37.0C
TEE T: 39.3C

JPEG

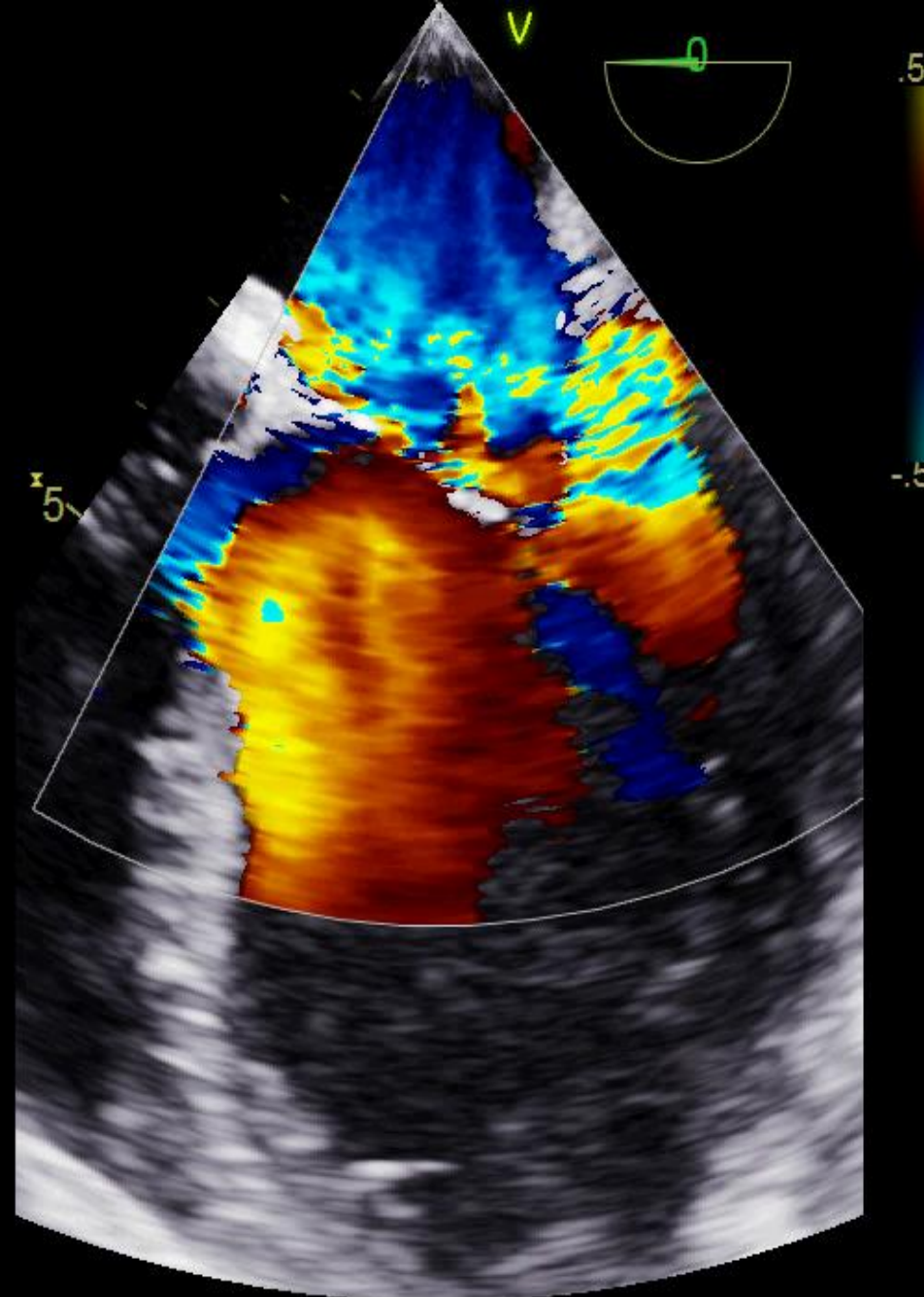
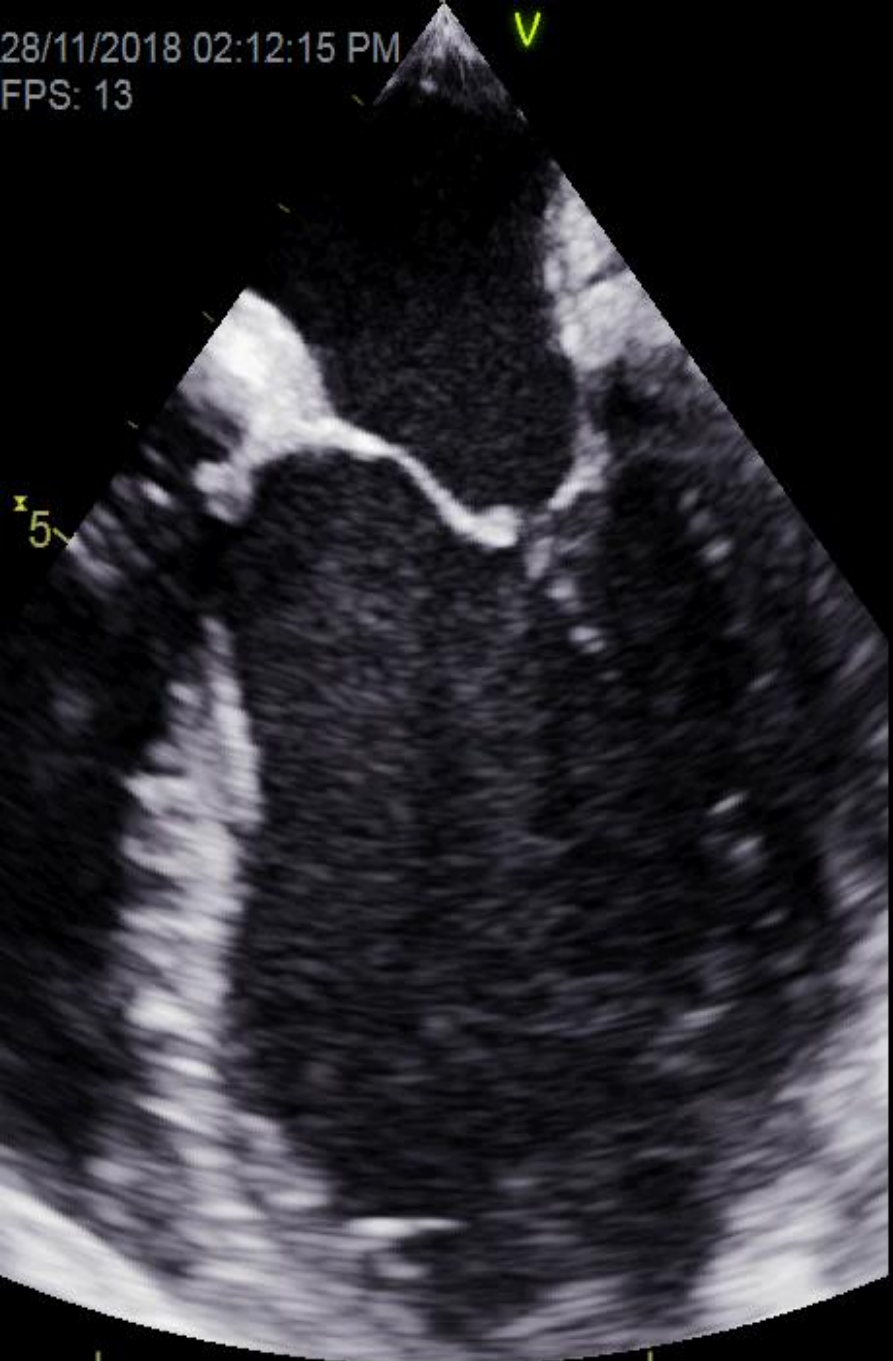70 bpm

- 
- The patient was advised for surgery and was transferred to HH
 - Another TEE was done

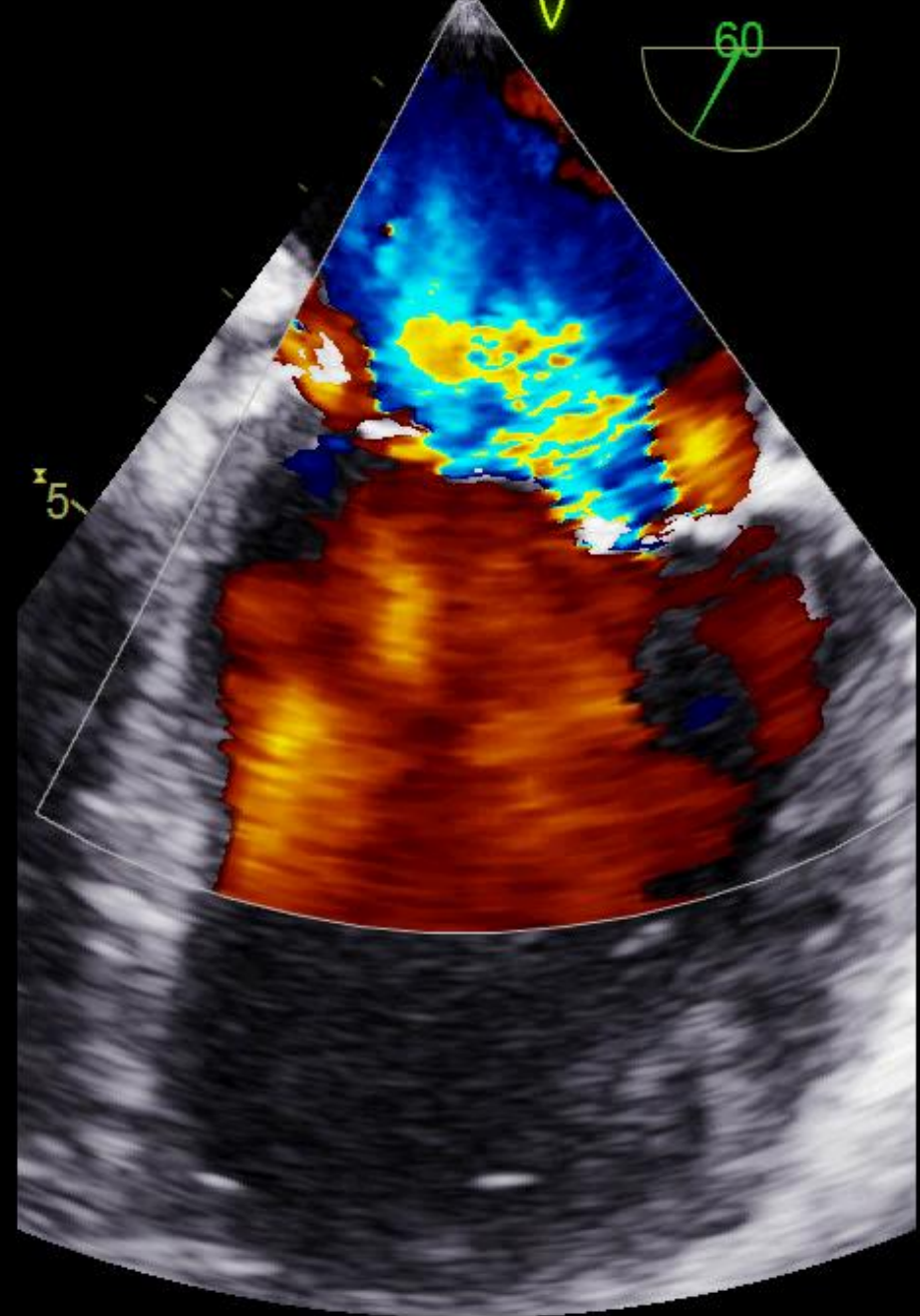
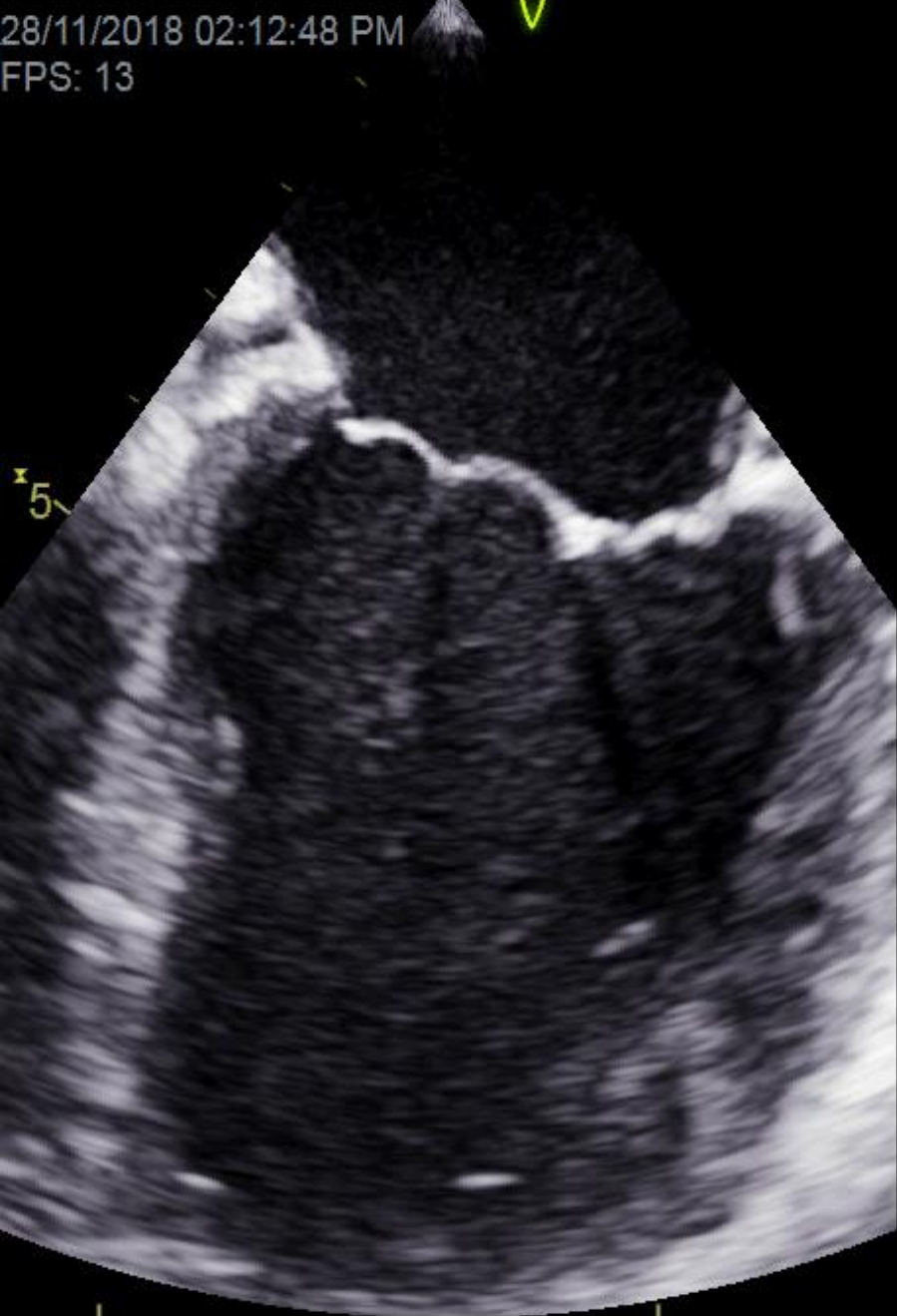

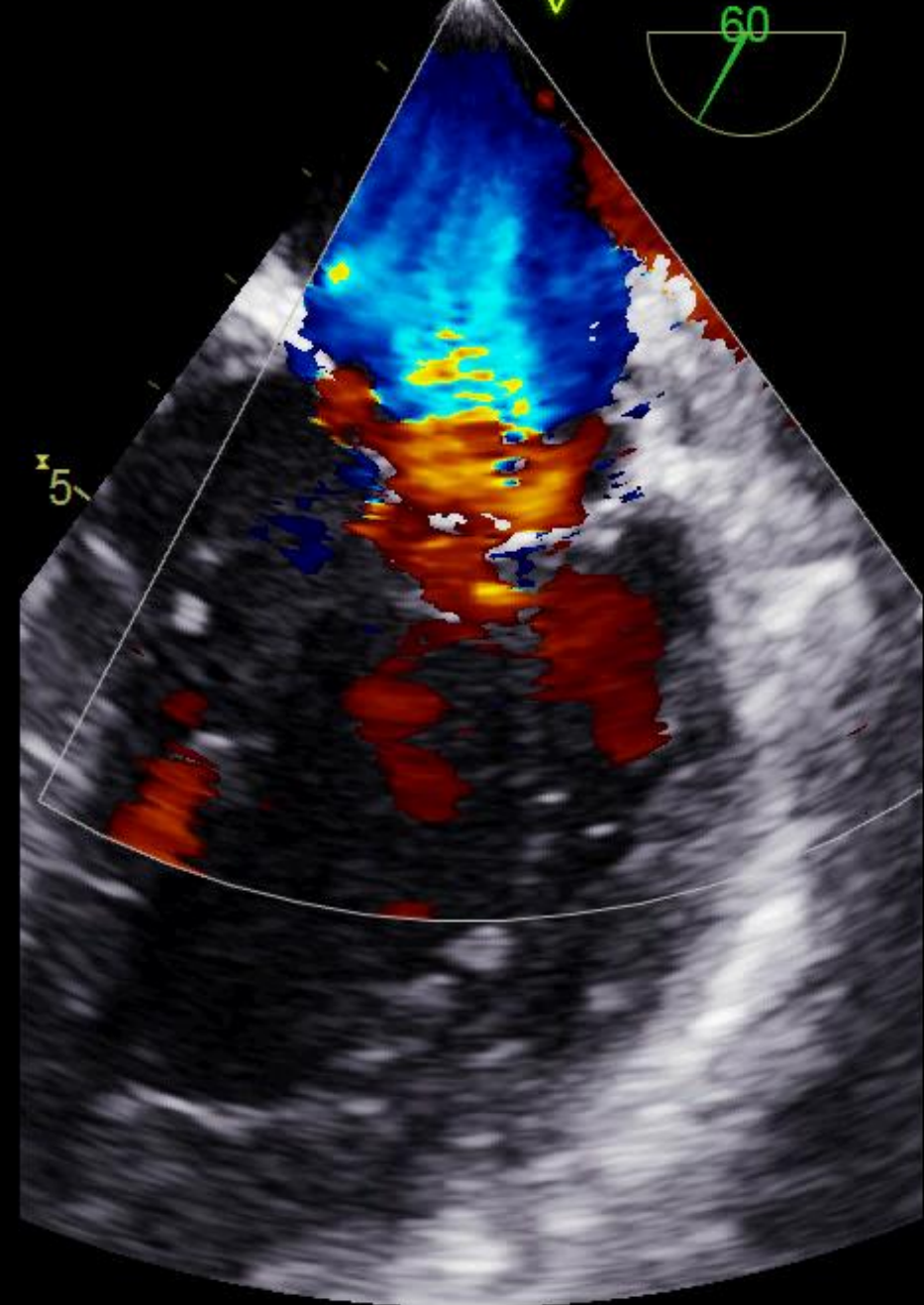

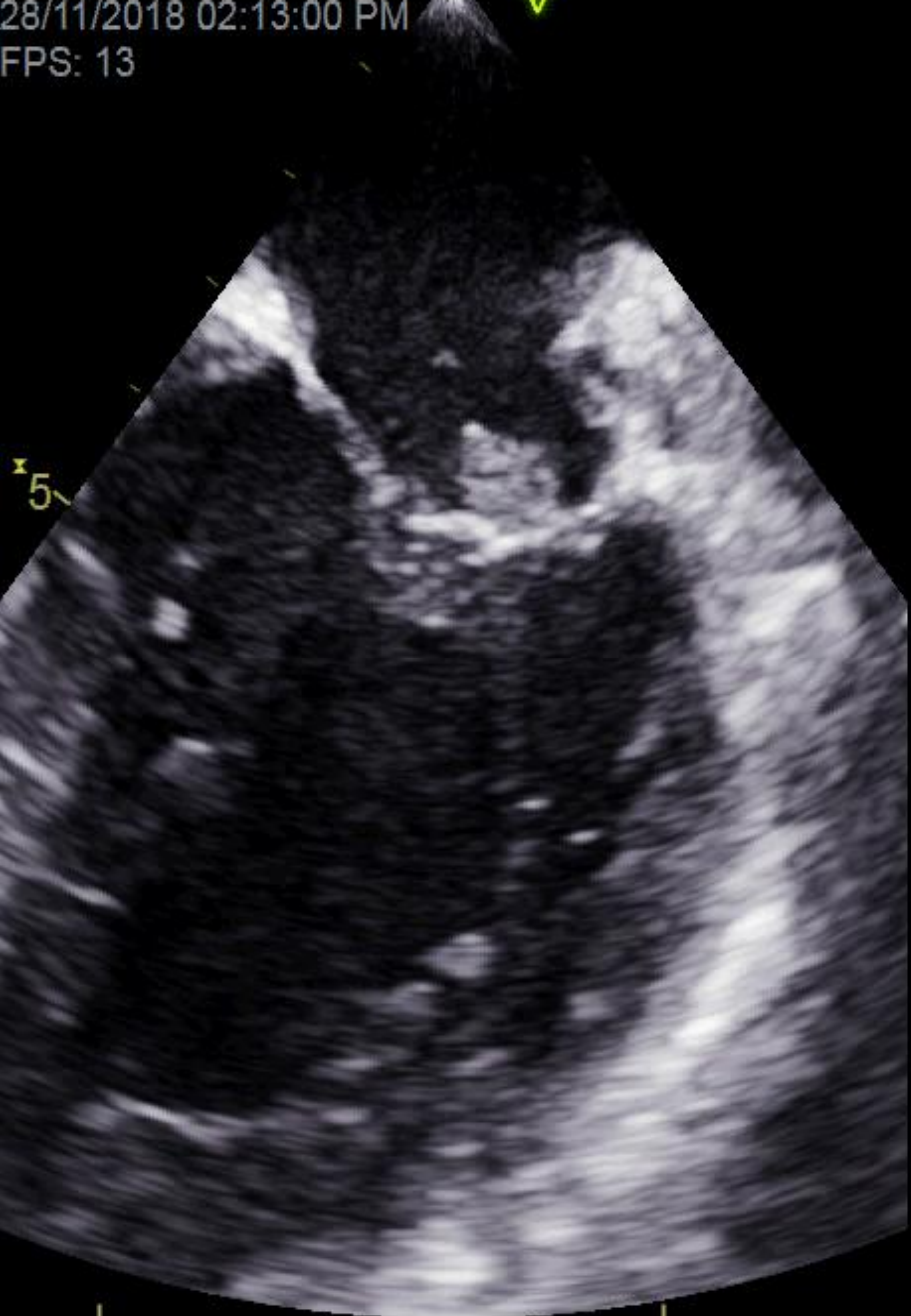
28/11/2018 02:12:15 PM
FPS: 13

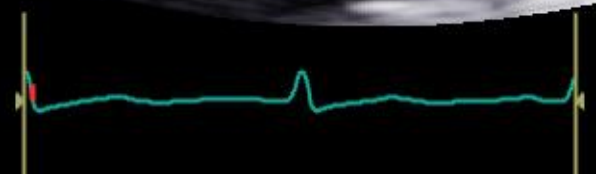
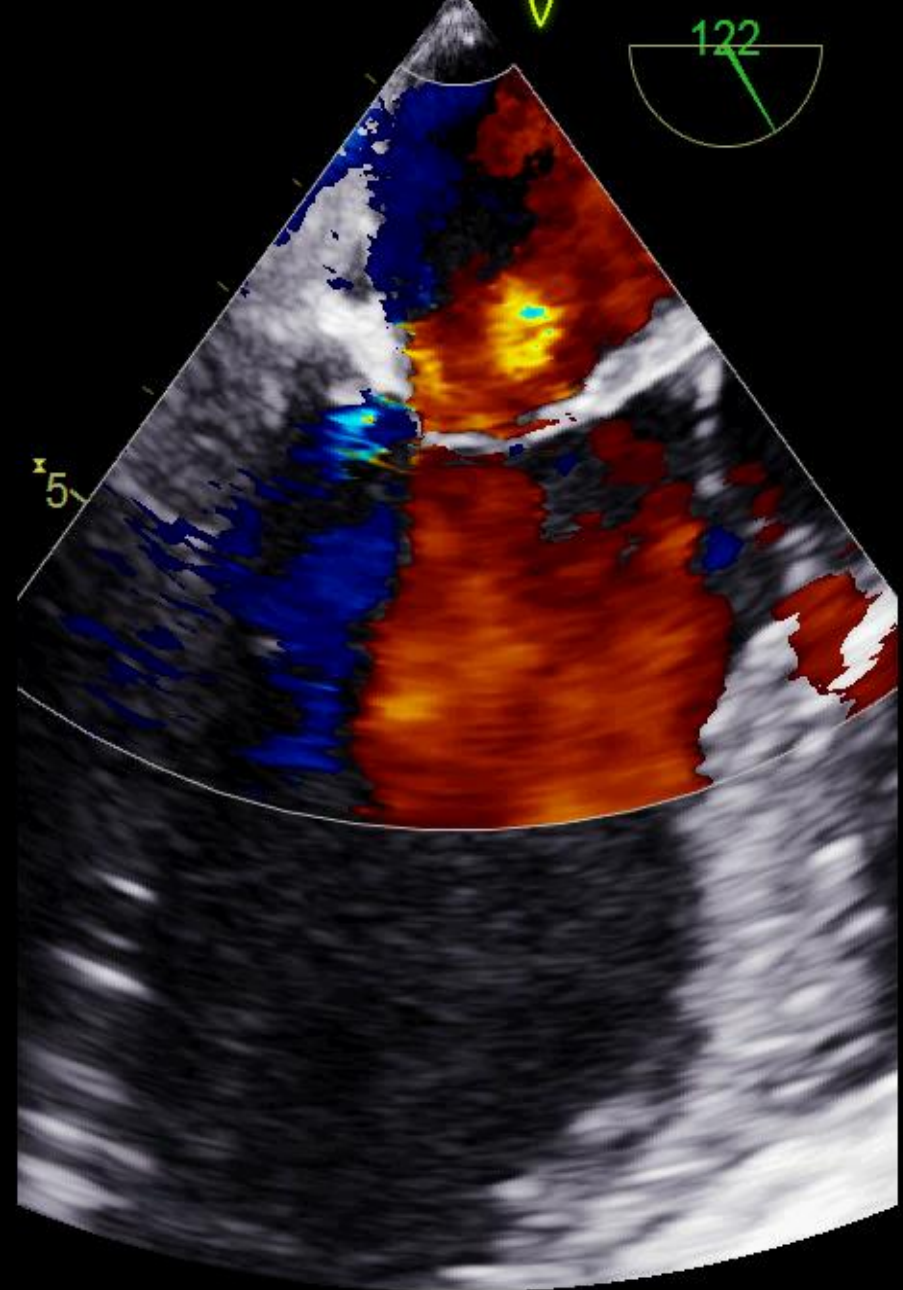
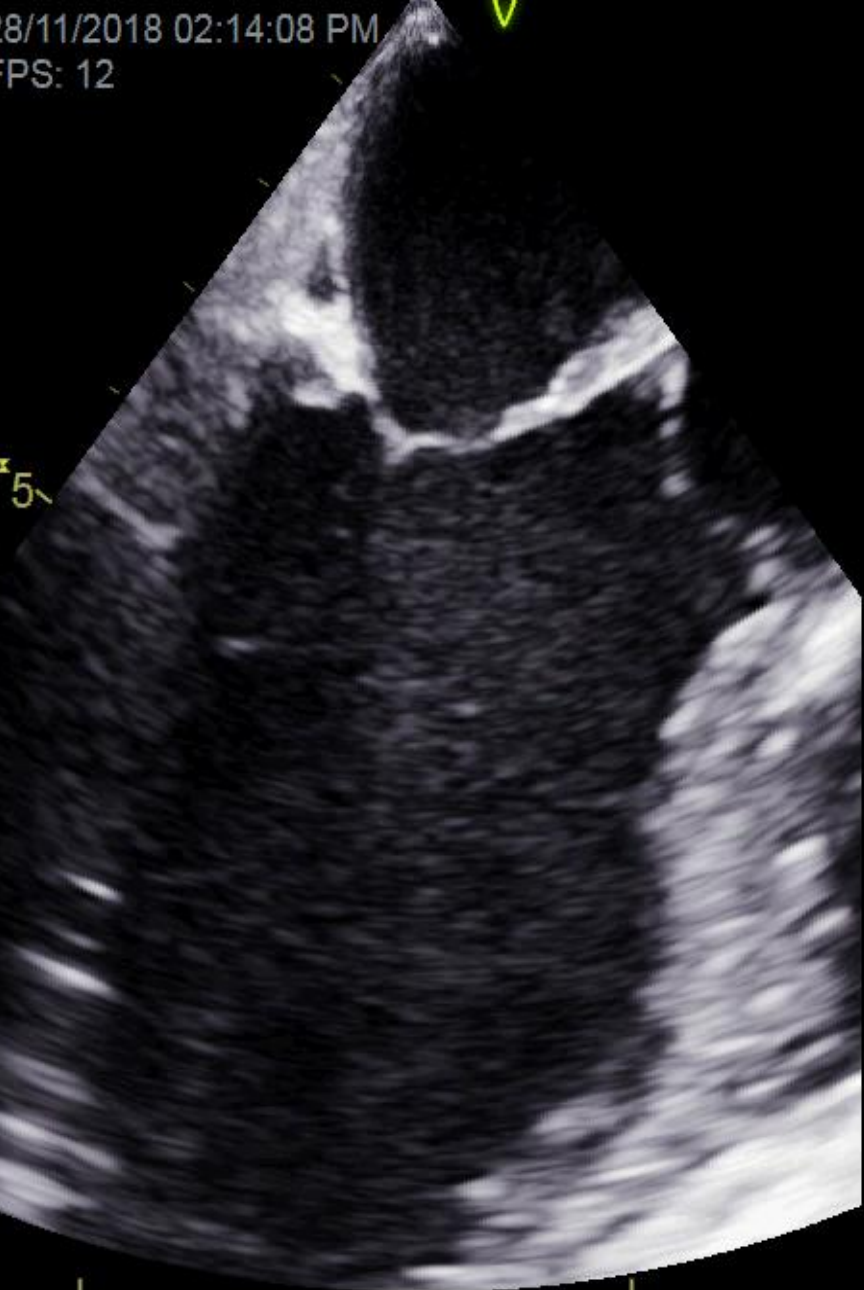

28/11/2018 02:12:48 PM
FPS: 13



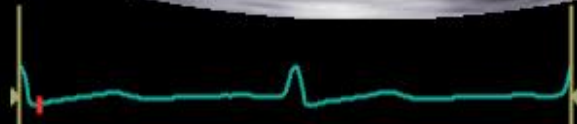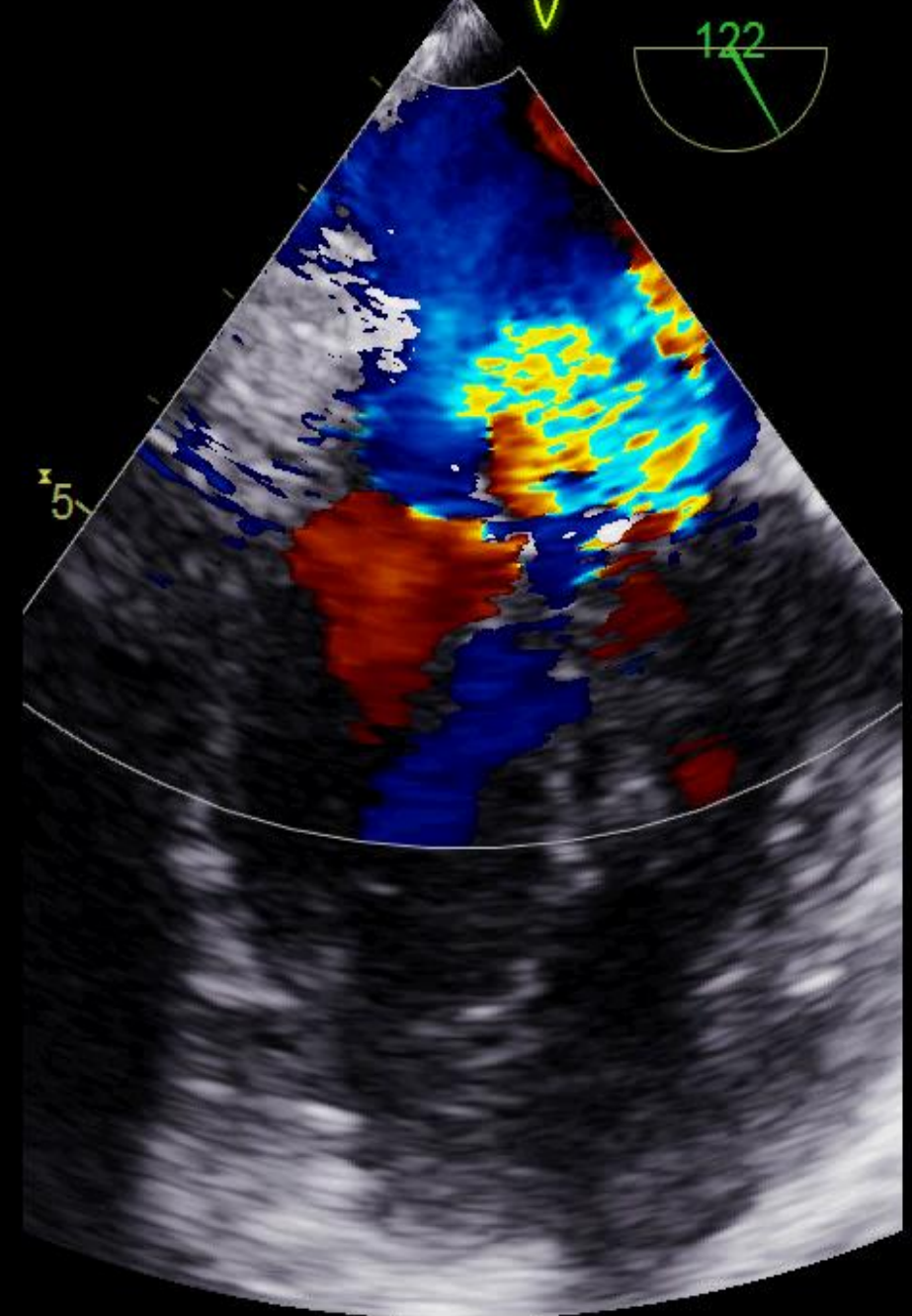
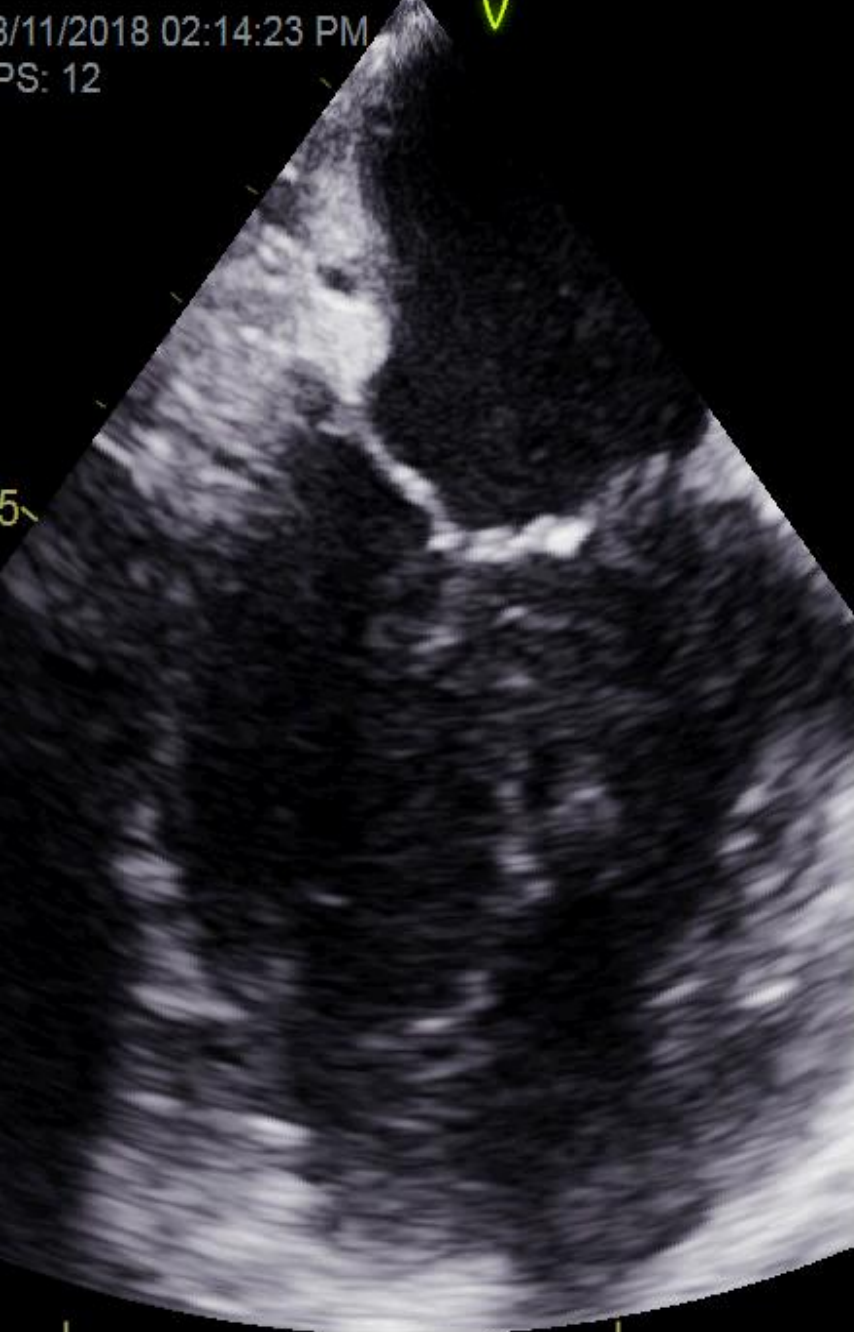


8/11/2018 02:14:08 PM
FPS: 12

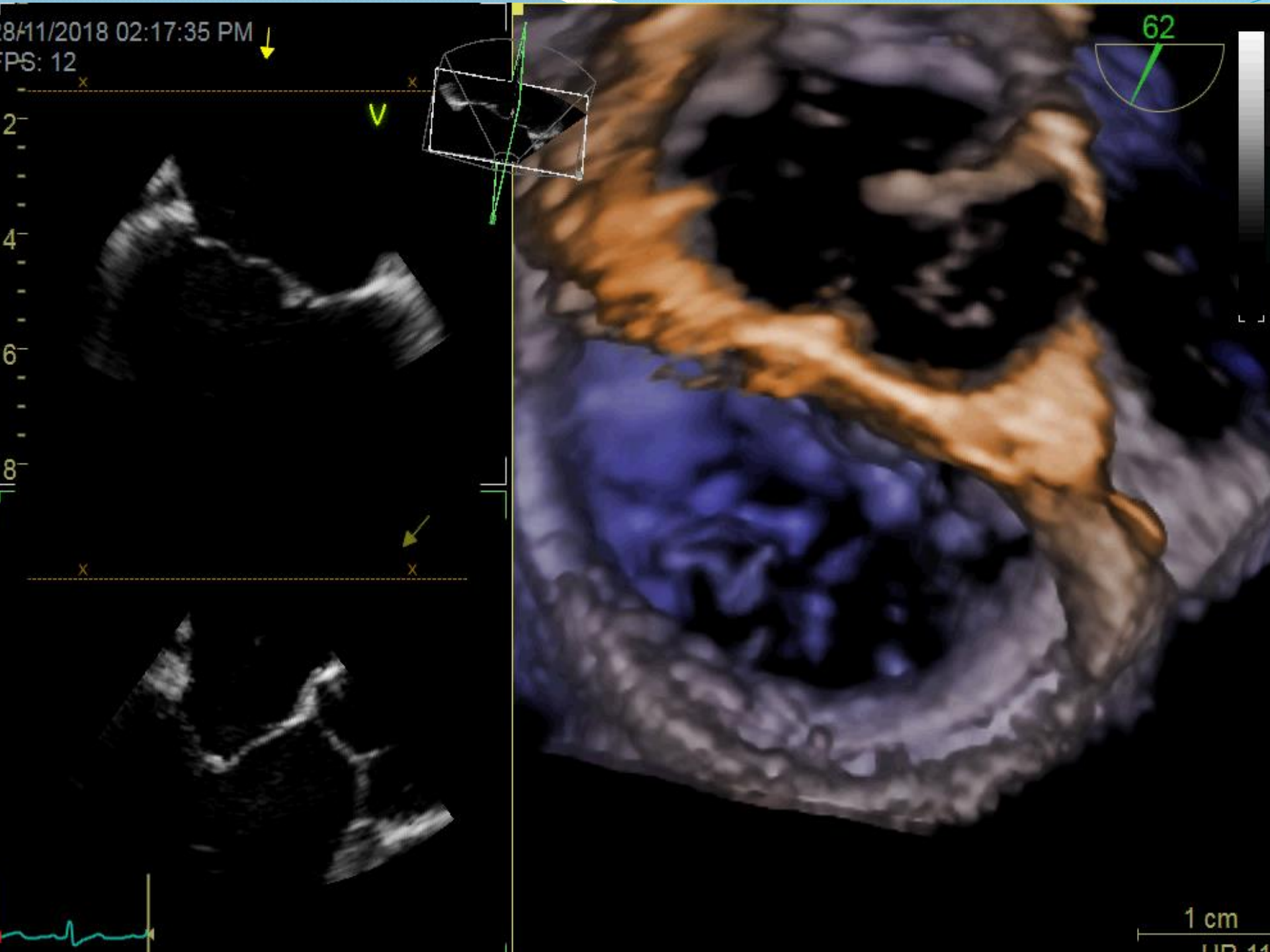


90
1:17HR

3/11/2018 02:14:23 PM
PS: 12




90



62

1 cm

UP 1

- 
- Pt refused surgery he wants to do it in his home country
 - Was discharged on Ab



thanks